

This is a self-archived version of an original article. This version may differ from the original in pagination and typographic details.

Author(s): Boyd, Sonja; Mustamäki, Taru; Sjöblom, Nelli; Nordin, Arno; Tenca, Andrea; Jokelainen, Kalle; Rantapero, Tommi; Liuksiala, Thomas; Lahtinen, Laura; Kuopio, Teijo; Kytölä, Soili; Mäkisalo, Heikki; Färkkilä, Martti; Arola, Johanna

Title: NGS of brush cytology samples improves the detection of high-grade dysplasia and cholangiocarcinoma in patients with primary sclerosing cholangitis : A retrospective and prospective study

Year: 2024

Version: Published version

Copyright: © 2024 The Author(s). Published by Wolters Kluwer Health, Inc. on behalf of the A

Rights: CC BY-NC-ND 4.0

Rights url: <https://creativecommons.org/licenses/by-nc-nd/4.0/>

Please cite the original version:

Boyd, S., Mustamäki, T., Sjöblom, N., Nordin, A., Tenca, A., Jokelainen, K., Rantapero, T., Liuksiala, T., Lahtinen, L., Kuopio, T., Kytölä, S., Mäkisalo, H., Färkkilä, M., & Arola, J. (2024). NGS of brush cytology samples improves the detection of high-grade dysplasia and cholangiocarcinoma in patients with primary sclerosing cholangitis : A retrospective and prospective study. *Hepatology Communications*, 8(4), Article e0415.
<https://doi.org/10.1097/HC9.0000000000000415>

ORIGINAL ARTICLE

OPEN

NGS of brush cytology samples improves the detection of high-grade dysplasia and cholangiocarcinoma in patients with primary sclerosing cholangitis: A retrospective and prospective study

Sonja Boyd¹  | Taru Mustamäki²  | Nelli Sjöblom¹  | Arno Nordin³  |
 Andrea Tenca⁴  | Kalle Jokelainen⁴  | Tommi Rantaperö⁵  |
 Thomas Liuksiala⁵  | Laura Lahtinen²  | Teijo Kuopio²  | Soili Kytölä⁶  |
 Heikki Mäkisalo³  | Martti Färkkilä⁴  | Johanna Arola¹ 

¹Department of Pathology, Helsinki University Hospital, University of Helsinki, Helsinki, Finland

²Department of Pathology, Hospital Nova of Central Finland University of Jyväskylä, Jyväskylä, Finland

³Department of Liver and Transplantation Surgery, Helsinki University Hospital, University of Helsinki, Finland

⁴Department of Gastroenterology, Helsinki University Hospital, University of Helsinki, Helsinki, Finland

⁵Genevia Technologies Oy Tampere, Finland

⁶Department of Genetics, Helsinki University Hospital, University of Helsinki, Finland

Correspondence

Sonja Boyd, Department of Pathology, P.O. Box 400, Haartmaninkatu 3 00029 HUS, Helsinki, Finland.
 Email: sonja.boyd@hus.fi

Abstract

Background: Biliary dysplasia, a precursor of cholangiocarcinoma (CCA), is a common complication of primary sclerosing cholangitis. Patients with high-grade dysplasia (HGD) or early CCA who have received oncological treatment are candidates for liver transplantation. The preoperative diagnosis of CCA or HGD is challenging, and the sensitivity of biliary brush cytology (BC) is limited.

Methods: By using next-generation sequencing (NGS), we retrospectively analyzed archived tissue samples (n = 62) obtained from explanted liver tissue and CCA samples to identify oncogenic mutations that occur during primary sclerosing cholangitis carcinogenesis. BC samples were prospectively collected from patients with primary sclerosing cholangitis (n = 97) referred for endoscopic retrograde cholangiography to measure the diagnostic utility of NGS combined with BC compared with traditional cytology alone.

Results: Mutations in *KRAS*, *GNAS*, *FLT3*, *RNF43*, *TP53*, *ATRX*, and *SMAD4* were detected in archived CCA or HGD samples. *KRAS*, *GNAS*, *TP53*, *CDKN2A*, *FBXW7*, *BRAF*, and *ATM* mutations were detected in prospectively collected brush samples from patients with histologically verified CCA or HGD. One patient with low-grade dysplasia in the

Abbreviations: BC, brush cytology; CA19-9, carbohydrate antigen 19-9; CCA, cholangiocarcinoma; ERC, endoscopic retrograde cholangiography; GBC, gallbladder carcinoma; HGD, high-grade dysplasia; LGD, low-grade dysplasia; LT, liver transplantation; NGS, next-generation sequencing; PSC, primary sclerosing cholangitis; UMI, unique molecular identifiers.

Martti Färkkilä and Johanna Arola contributed equally.

Supplemental Digital Content is available for this article. Direct URL citations are provided in the HTML and PDF versions of this article on the journal's website, www.hepcommjournal.com.

This is an open access article distributed under the terms of the Creative Commons Attribution-Non Commercial-No Derivatives License 4.0 (CCBY-NC-ND), where it is permissible to download and share the work provided it is properly cited. The work cannot be changed in any way or used commercially without permission from the journal.

Copyright © 2024 The Author(s). Published by Wolters Kluwer Health, Inc. on behalf of the American Association for the Study of Liver Diseases.

explanted liver had *KRAS* and *GNAS* mutations in brush sample. No mutations were observed in brush samples or archived tissues in liver transplantation cases without biliary neoplasia. While *KRAS* mutations are common in biliary neoplasms, they were also observed in patients without biliary neoplasia during surveillance.

Conclusions: In summary, NGS of BC samples increased the sensitivity of detecting biliary neoplasia compared with traditional cytology. Performing NGS on BC samples may help diagnose HGD or early CCA, benefiting the timing of liver transplantation.

INTRODUCTION

Primary sclerosing cholangitis (PSC) is a chronic cholestatic disease that can lead to cholangiocarcinoma (CCA) and/or liver cirrhosis. The prevalence of PSC is particularly high in Finland, and the risk of CCA among patients with PSC is 9%–13%, or 200-fold higher than that in the general population.^[1–3] CCA causes most cancer-related deaths among patients with PSC^[4] and, like many other cancers, appears to develop sequentially from inflammation, followed by metaplasia, low-grade dysplasia (LGD), high-grade dysplasia (HGD), and carcinoma.^[5] Brush cytology (BC) is generally recommended to identify dysplasia or CCA in patients with PSC.^[6]

The main precursors of CCA are biliary intraepithelial neoplasia (dysplasia) and intraductal papillary neoplasms of the bile duct.^[7] Intrahepatic and extrahepatic or distal CCAs have distinct morphologies;^[8] however, PSC-associated CCA often have a large duct morphology, regardless of localization.^[7] Furthermore, although intrahepatic and extrahepatic CCAs have slightly different molecular profiles,^[9–11] the molecular profile of PSC-associated CCA is similar to that of extrahepatic CCA—including mutations in *TP53*, *KRAS*, *CDKN2A*, and *SMAD4*—regardless of tumor location.^[7] Some mutations are already present in dysplastic bile ducts and PSC-associated CCA; however, copy number variations appear early in cholangiocarcinogenesis.^[12] Importantly, identifying HGD before its progression to invasive CCA is vital for early liver transplantation (LT) or, in cases with early CCA, LT after neoadjuvant chemoradiation.^[13]

At Helsinki University Hospital, early LT is an option for patients suspected of having biliary HGD,^[14] and dysplasia screening is regularly performed using endoscopic retrograde cholangiography (ERC) with BC.^[15] The sensitivity and specificity of BC for detecting biliary malignancies in PSC-associated CCA are 43% and 97%, respectively.^[16] We previously reported that repeated BC has a sensitivity and specificity of 71% and 91%, respectively, for detecting biliary neoplasia in patients

with PSC with systematic surveillance using ERC and BC.^[15] A targeted next-generation sequencing (NGS) panel has been shown to improve the detection of malignant biliary strictures from 35% to 77% compared with traditional BC.^[17] However, although NGS-based analysis of cell-free bile DNA increases the sensitivity (100%) for detecting malignant biliary strictures, it is less specific than BC.^[18] Therefore, it is necessary to evaluate new diagnostic approaches for improving patient management.

To assess the molecular profile of PSC carcinogenesis, we retrospectively investigated the molecular findings in archived explanted liver tissue samples of PSC-associated histologically confirmed cases of CCA and biliary dysplasia. Using prospectively collected BC samples analyzed via NGS, we aimed to determine whether molecular changes can support the diagnosis of biliary neoplasia in patients with PSC compared to traditional cytology and improve the timing of early LT. Establishing NGS as a tool for detecting biliary neoplasia may lead to earlier identification of candidates suitable for early LT and, thus, improvements in patient outcomes.

METHODS

Study design

This retrospective and prospective study included 2 separate cohorts of patients with PSC. In this retrospective study, histological and NGS analyses were performed using archived paraffin tissue blocks from patients with PSC with explanted liver and/or histological samples from CCA. Histological samples were collected between December 2000 and May 2020. In the prospective study, brush samples were collected during ERC and analyzed using cytology and NGS. ERCs were performed between May 2019 and June 2022. Patients who reached the end point (LT, histologically verified CCA, or 1-year surveillance with no signs of malignancy) by February 2023 were included in this study.

Patients

Patients were identified from the PSC Registry of the Helsinki University Hospital. PSC diagnosis was confirmed using magnetic resonance cholangiography and ERC, which were performed as described.^[19] The ERC results were classified according to the Helsinki score.^[19] Written informed consent was obtained from all patients, and the study protocol was approved by the ethics committee of Helsinki University Hospital (HUS/1566/2020). The study was conducted in accordance with both the Declarations of Helsinki and Istanbul.

Retrospective cohort

To investigate the molecular changes in biliary neoplasias and compare them with histologically benign bile ducts, we retrospectively analyzed histological samples from patients with PSC (Figure 1A) who underwent LT and/or were diagnosed with histologically verified CCA. A large NGS panel (QIAseq Targeted DNA Panel Human Comprehensive Cancer Panel) was used. The results from the latest BC before LT or CCA diagnosis were collected.

Among the 75 patients, sufficient DNA amount or sequencing quality was reached for 62 patients, of whom 55 underwent transplantation indicated for either end-stage liver disease or symptoms of end-stage liver disease ($n = 37$) or suspicion of biliary neoplasia ($n = 18$, early LT). Preoperative assessment identified 7 patients diagnosed with CCA who did not undergo transplantation. All patients with CCA ($n = 10$) had histological samples showing primary or metastatic CCA; 1 patient was diagnosed with gallbladder carcinoma (GBC), 6 with HGD, and 12 with LGD in the explanted liver (Table 1). In one patient with CCA, samples from bile ducts with HGD were analyzed because of the low DNA content of samples obtained from the CCA site. Explanted livers with LGD or without biliary neoplasia were included in the analysis to evaluate whether pathogenic NGS findings were observed in LGD, histologically benign bile ducts, or areas interpreted as indefinite for dysplasia.

Representative histological slides were scanned in the retrospective cohort, and a liver pathologist (Sonja Boyd) reviewed the histological findings. Representative CCA, GBC, HGD, LGD, and benign biliary epithelium areas were annotated using CaseViewer software (3dHistec, Budapest, Hungary); 1–4 punches (diameter: 1 mm) were extracted from each location using a TMA Grand Master (3dHistec). After punching, a new histological section was cut from the block and stained with hematoxylin and eosin to confirm the correct location of the punch. DNA was extracted from the tissue block punches using a QIA Symphony DSP

DNA Mini Kit (Qiagen, Hilden, Germany) according to the manufacturer's instructions.

Gene libraries were prepared according to the manufacturer's instructions using the targeted DNA panel QIAseq Comprehensive Cancer Panel with unique molecular identifiers (UMI) (Qiagen). Paired-end sequencing (2×150 cycles) was performed using an Illumina NextSeq500 (Illumina Inc., San Diego, CA) according to the manufacturer's instructions. Variants were called using the Qiagen CLC Genomics Workbench (version 20.0.2) with the Qiagen workflow. Variants with frequencies of $< 2\%$ were filtered from the final list of variants. Variants were annotated using Variant Effect Predictor version 104^[20] and CRAVAT version 5.2.4.^[21]

The minimum average read depth for number of UMI was set to 100. The average UMI depth was 349 UMIs for all samples (range, 103–1192 UMI). To remove likely false-positive mutations, postquality filtering required that the depth at the mutation site and number of reads supporting the alternative allele be > 20 and > 10 UMI reads, respectively. A variant allele fraction of 0.025 was also required at the mutation site. From the remaining set of mutations, likely germline variants were filtered out by requiring the variant allele fraction of the mutations and the reported maximum population allele frequency in any population database to be ≤ 0.25 and < 0.001 , respectively. Furthermore, all mutations reported in Database for Single Nucleotide Polymorphisms (<https://www.ncbi.nlm.nih.gov/snp/>) were excluded unless they were also reported in Catalogue of Somatic Mutations in Cancer (<https://cancer.sanger.ac.uk/cosmic>). Putative cancer-driving somatic mutations were identified based on the impact of the mutation (according to Variant Effect Predictor) as moderate or high with either the Cancer Specific High-throughput Annotation of Somatic Mutations or Variant Effect Scoring Tool score > 0.7 . All filtering procedures were performed using in-house Python scripts, and the oncoplot was prepared using the “maftools” R package, version 4.0.3.^[22]

Prospective cohort

Patients with PSC in Helsinki University Hospital have regular ERCs to screen for biliary dysplasia. The frequency of ERC depends on the severity of the disease, previous BC/NGS findings, and the need for dilation (Supplemental Figure S1, <http://links.lww.com/HCG9/A838>). Suspicious BC or NGS findings are evaluated in a multidisciplinary team and if biliary HGD is suspected based on the results, patients are referred for evaluation of LT. To analyze molecular and cytological findings in brush samples of patients with PSC with histologically verified end point (LT and/or CCA) or benign follow-up, brush samples were systematically collected regardless of the dominant strictures.

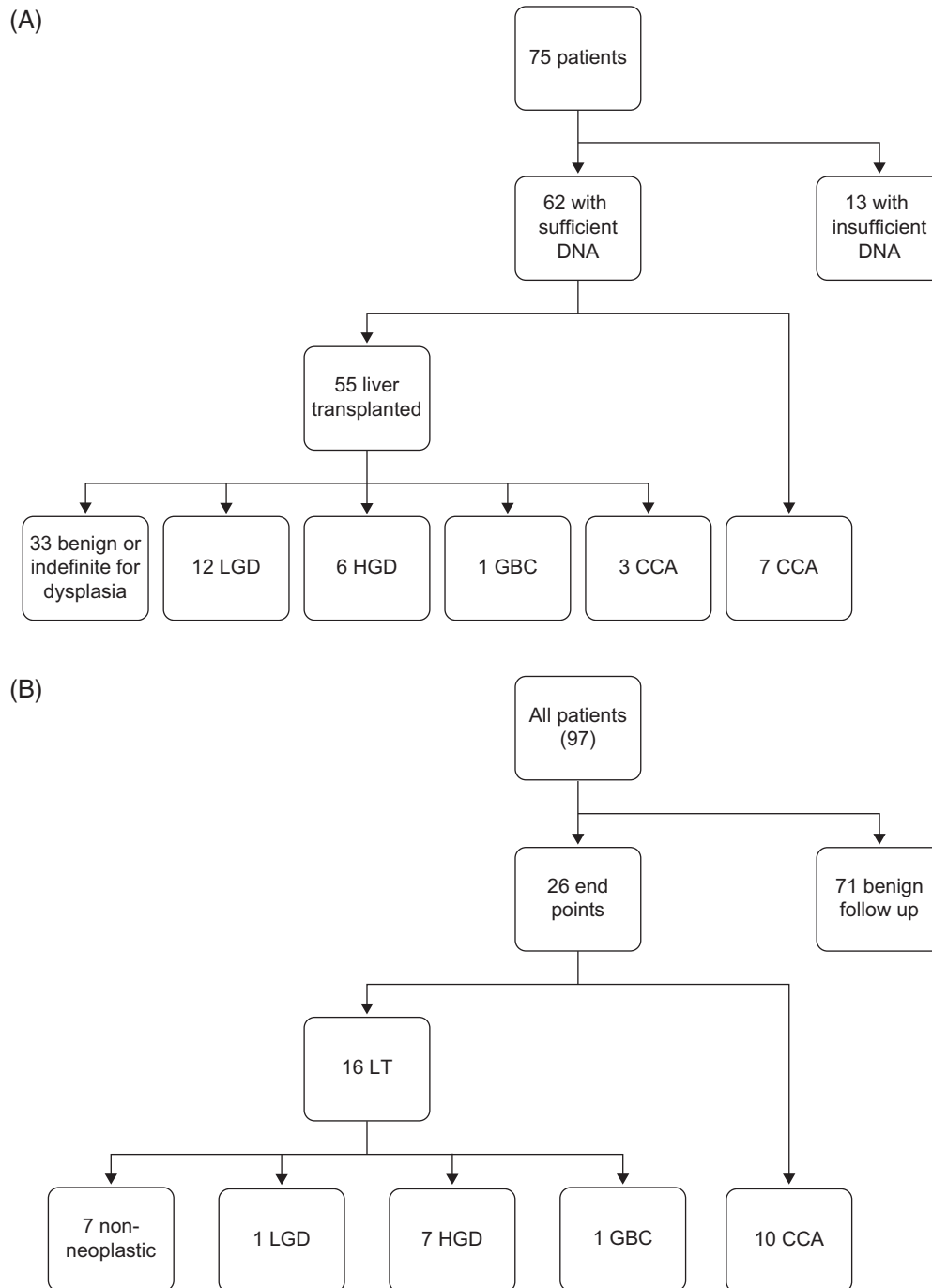


FIGURE 1 (A) Patients in the retrospective cohort. (B) Patients in the prospective cohort. Abbreviations: CCA, cholangiocarcinoma; GBC, gallbladder carcinoma; HGD, high-grade dysplasia; LGD, low-grade dysplasia; LT, liver transplantation.

The total number of patients in ERC surveillance during the study period was 565, and the number of ERCs was 913. Among these, 97 patients had NGS performed due to clinical suspicion of CCA, dominant stricture, elevated carbohydrate antigen 19-9 (CA19-9) levels, or a history of suspicious cytology and were enrolled in the study (Figure 1B). Altogether, 176 ERCs were performed during the study period for the patients included in the study. Helsinki ERC scores^{19]} and

serum CA19-9 levels were recorded. A hotspot NGS gene panel targeting 50 oncogenes (Ion AmpliSeq Cancer Hotspot Panel v2; Thermo Fischer Scientific, Waltham, MA) was used for the BC samples.

BC was collected systematically from both extrahepatic and intrahepatic (left and right) bile ducts using a brush with a guide wire (RX Cytology Brush, Boston Scientific, MA), regardless of possible dominant stricture using one brush and to reach as many branches as possible. In case

of suspicious lesion, a targeted brush sample was also obtained. Brush samples were collected in 50% ethanol, and Papanicolaou staining was performed on cytocentrifuge slides. If there was sufficient material, cell blocks were prepared and stained with hematoxylin and eosin. The brush samples were evaluated by liver pathologists (Sonja Boyd and Johanna Arola) and interpreted as being benign, suspicious, or malignant. Alcohol was removed from the remaining BC material, and DNA was extracted using the Maxwell CSC Blood DNA Kit (Promega, Madison, WI) according to the manufacturer's instructions.

DNA was subjected to library preparation using Ion AmpliSeq Cancer Hotspot Panel version 2 (designed to target 2800 Catalogue of Somatic Mutations in Cancer (<https://cancer.sanger.ac.uk/cosmic>) mutations from 50 oncogenes and tumor suppressor genes) and sequenced in both forward and reverse directions on an Ion Torrent Proton and S5Prime System (Thermo Fisher Scientific). Library preparation, template preparation, and sequencing were performed according to the manufacturer's instructions. Minimum depth of coverage was 500. Data analysis was performed using Torrent Suite Software version 5.12.3. After trimming and aligning to the hg19 human reference genome, sequence variants were detected using VariantCaller version 5.12.0.4. Ion Reporter software version 4.6 was used to filter noncoding, synonymous, and germline polymorphic variants. Gene mutations were defined using an amplicon sequencing panel capable of identifying mutations with a variant allele frequency > 1%–2%.

Statistical analysis

The detection of high-grade biliary neoplasia (HGD or CCA) in the prospective cohort was assessed using 3 alternatives (BC alone, NGS alone, and BC + NGS) for all patients and separately for histologically verified patients only. The sensitivity, specificity, positive predictive value, and negative predictive value were calculated, and 95%

CI were estimated using the Clopper-Pearson method (for sensitivity and specificity) and a logit-based approach (for positive predictive value and negative predictive value). The analysis was performed using R statistical software.^[23]

RESULTS

NGS findings in the retrospective cohort

In the retrospective cohort ($n=62$), 10 patients had CCA, 1 had GBC, and 6 had HGD. Among them, pathogenic mutations were found in DNA extracted from archived tissue blocks in 11/17 (65%) samples, and previous BC was suspicious for malignancy in 13/17 (Table 1). The most frequently mutated genes were *KRAS*, *GNAS*, *RNF43*, *FLT3*, and *TP53* (Figure 2). *TP53* and *SMAD4* mutations were identified in the explanted liver of 1 patient, histologically interpreted as LGD. One patient with CCA had only HGD areas analyzed, and pathogenic mutations in multiple genes, including *ATRX* and *MSH6* were detected. There were no pathogenic mutations in benign bile duct samples or regions interpreted as indefinite for dysplasia.

Histological findings in the prospective cohort

The objective of this prospective cohort analysis was to assess the prevalence of pathogenic mutations in prospectively collected BC compared with traditional BC findings to evaluate the additional role of NGS in the early diagnosis of HGD and CCA. In the prospective cohort, 18/97 (19%) patients were diagnosed with CCA, GBC, or HGD during the study period, 8 underwent LT, and 10 had other histological verifications (Table 2). None of the patients who underwent LT had CCA; however, 1 patient was diagnosed with GBC after LT. Two patients with distal intrapancreatic CCA underwent pancreatoduodenectomy. One patient who underwent LT had LGD in the explanted liver.

TABLE 1 Demographic and clinical characteristics of the patients in the retrospective analysis

	N	Suspicious BC	NGS mutations by histology
All patients, n (M/F)	62 (38/24)	23	12
Biliary neoplasia, n (M/F), all including LT	29 (19/10)	19	12
CCA (M/F)	10 (6/5)	8	8
GBC (M/F)	1 (0/1)	0	0
HGD (M/F)	6 (4/2)	5	3
LGD (M/F)	12 (9/3)	6	1
LT, n (M/F)	55 (33/22)	18	6
End-stage liver disease or symptoms	37 (19/18)	2	1
Biliary neoplasia suspected	18 (14/4)	16	5
Patients with CCA who did not undergo LT (M/F)	7 (5/2)	5	6

Abbreviations: BC, brush cytology; CCA, cholangiocarcinoma; F, female; GBC, gallbladder carcinoma; HGD, high-grade dysplasia; LGD, low-grade dysplasia; LT, liver transplantation; M, male; NGS, next-generation sequencing.

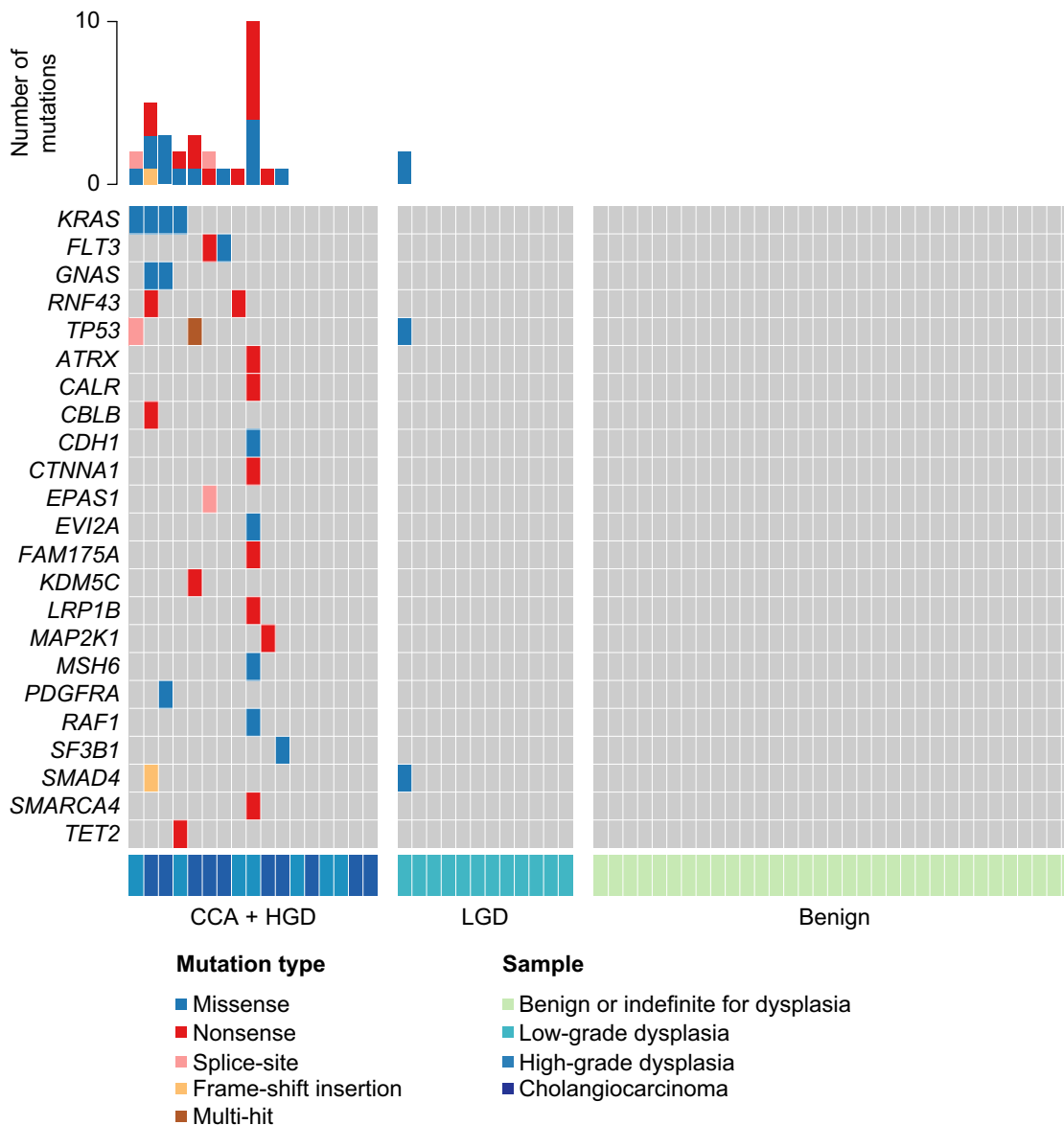


FIGURE 2 Oncoplot image of the next-generation sequencing results of the retrospective cohort. One patient with gallbladder carcinoma having no mutations by next-generation sequencing is included in the patients with CCA. Abbreviations: CCA, cholangiocarcinoma; HGD, high-grade dysplasia; LGD, low-grade dysplasia.

NGS and BC findings in patients with CCA

Ten patients were diagnosed with CCA, 8 had suspicious NGS results based on BC samples, including mutations in *TP53*, *CDKN2A*, *GNAS*, *BRAF*, *FBXW7*, *ATM*, and *KRAS* (Table 3, Figure 3), and BC was suspicious for malignancy in 6. Cytology was not evaluated as malignant in any of the patients. One patient with CCA had a *KRAS* mutation only, and one with intrahepatic CCA had negative NGS and cytological results. One patient had GBC with negative cytology and NGS results. Serum CA19-9 levels ranged from 2 to 1165 kU/L among patients with CCA or GBC and were elevated (> 37 kU/L) in 3 of them.

NGS and BC findings in patients with biliary dysplasia

HGD of the perihilar bile ducts was diagnosed in 7 patients who underwent LT. NGS (*CDKN2A*, *TP53*, or *GNAS* mutations) and cytology were suspicious in 4 and 5 cases, respectively. One patient had cytology findings suspicious of malignancy and *KRAS* and *GNAS* mutations; however, only LGD was observed in the perihilar bile ducts of the explanted liver. None of the patients with HGD or LGD had elevated serum CA19-9 levels.

TABLE 2 Histology, brush cytology, NGS, CA19-9, and ERC findings in the prospective cohort

	Total	Suspicious BC	Suspicious NGS	NGS <i>KRAS</i> only	CA19-9 kU/L mean/median (range)	ERC Intrahepatic/Intrahepatic and extrahepatic disease
All patients, n	97	17	14	11	194/9 (2–14,201 ^a)	21/76
Liver transplantation, n	16	6	5	0	31/18 (2–231)	4/12
HGD	7	5	4	0	10/4 (2–36)	2/5
GBC	1	0	0	0	26/26 (26)	0/1
LGD	1	1	1	0	9/9 (9)	1/0
No biliary neoplasia in explanted liver	7	0	0	0	57/26 (7–231)	1/6
CCA	10	6	8	1	197/21 (2–1165)	1/9
Benign follow-up > 1 y	71 ^a	5	1	10 ^a	230/9 (2–14,201 ^a)	16/55

Note: Suspicious NGS was defined as a pathogenic mutation in *TP53*, *CDKN2A*, *GNAS*, *ATM*, *BRAF*, or *FBXW7* + a mutation in *KRAS*. NGS *KRAS* only was defined as a pathogenic mutation in the *KRAS* gene only.

^aIncluding 1 patient with colorectal carcinoma metastasis to the liver but no biliary neoplasia. Serum CA19-9 value in this patient was 14,201 kU/L.

Abbreviations: BC, brush cytology; CCA, cholangiocarcinoma; ERC, endoscopic retrograde cholangiography; GBC, gallbladder carcinoma; HGD, high-grade dysplasia; LGD, low-grade dysplasia; NGS, next-generation sequencing.

NGS and BC findings in patients with no biliary neoplasia

Among the 7 patients who underwent LT due to symptoms or cirrhosis, there was no biliary neoplasia in the explant, and all patients had benign BC and were negative for mutations by NGS in brush samples. One patient with a suspicious NGS finding (*PIK3CA* mutation) was not diagnosed with biliary neoplasia during surveillance and did not undergo LT.

Patients with *KRAS* mutation only by NGS

Eleven patients had only *KRAS* mutations, one was diagnosed with CCA, one had colorectal carcinoma metastasis to the liver, and the remaining nine remained under surveillance without signs of malignancy.

In summary, 80% of the patients with CCA had suspicious NGS results. Altogether, 14 patients (14%) had suspicious NGS findings during surveillance, and 13 were diagnosed with biliary neoplasia (CCA, HGD, or LGD). In contrast, none of the patients who underwent LT for cirrhosis or symptoms with benign BC and negative NGS results showed biliary neoplasia in the explant.

Follow-up NGS samples

In 49 patients, only 1 NGS sample was obtained during the study period; follow-up samples were obtained from 48 patients ($n = 2-7$ /patient). Among the patients who reached the histologically verified end point (LT or CCA, $n = 26$), 17 and 9 had 1 and 2–3 NGS samples, respectively.

Persistent NGS mutations

In 34 patients with repeated sampling, the NGS results remained the same. In one patient diagnosed with CCA, the NGS findings remained the same after the first analysis, and the same *TP53* mutation was identified 4 times.

Mutations after repeated NGS

The results of BC and NGS analyses are presented in Figure 4. In one patient, *GNAS* and *FBXW7* mutations were observed during the first NGS analysis. In subsequent analysis, *KRAS* and *TP53* mutations were observed, but no *FBXW7* mutations were detected. The patient was diagnosed with CCA. In another patient, only *KRAS* mutation was detected in the first NGS analysis, but a *TP53* mutation was identified in the subsequent analysis. The patient was diagnosed with CCA.

Lost mutations after repeated NGS

In one patient diagnosed with CCA, *GNAS* and *BRAF* mutations were observed twice; however, only 1 *GNAS* mutation was observed in a subsequent sample. In another patient diagnosed with HGD of explanted liver tissue, *CDKN2A*, *TP53*, and *KRAS* mutations were detected in the first NGS analysis, but only *CDKN2A* mutations were detected in the 2 subsequent samples.

TABLE 3 Patients in the prospective cohort with histologically verified neoplasia

Histology (type)	NGS in brush samples	Histological diagnosis	Brush cytology	ERC score (1–16)	CA19-9	Tumor localization
CCA (large duct)	<i>GNAS</i> Arg201Cys <i>FBXW7</i> Arg479Gln <i>TP53</i> Lys132Glu <i>KRAS</i> Gly12Val	Liver biopsy	Suspicious	8	3	Intrahepatic
CCA (large duct)	<i>TP53</i> Pro151Ser <i>TP53</i> Trp91Ter <i>KRAS</i> amplification	Liver and lymph-node biopsy	Suspicious	10	658	Perihilar
CCA (NA)	<i>GNAS</i> Arg201Cys <i>BRAF</i> Asp594Asn	Lymph-node metastasis surgical sample	Suspicious	12	11	NA
CCA (NA)	<i>KRAS</i> Gly12Asp <i>TP53</i> His179Tyr	Lymph-node metastasis surgical sample	Suspicious	13	60	NA
CCA (NA)	<i>TP53</i> Ser241Cys	Choledochal duct surgical biopsy	Suspicious	6	31	Perihilar
CCA (large duct)	<i>CDKN2A</i> Arg80Ter <i>KRAS</i> Gly12Asp <i>TP53</i> Cys242Phe <i>TP53</i> Gly245Ser	Pancreatoduodenectomy	Suspicious	12	33	Distal
CCA (large duct)	<i>TP53</i> Arg248Gln	Pancreatoduodenectomy	Negative	6	2	Distal
CCA (NA)	<i>ATM</i> Gln2730Arg	Lymph-node metastasis surgical sample	Negative	8	2	Perihilar
CCA (small duct)	<i>KRAS</i> Gly12Asp	Liver biopsy	Negative	4	1165	NA
CCA (NA)	No mutations	Liver biopsy	Negative	10	6	Intrahepatic
GBC	No mutations	Liver transplantation	Negative	10	26	Gallbladder
HGD	<i>KRAS</i> Gly12Val <i>CDKN2A</i> Arg80Ter	Liver transplantation	Suspicious	6	2	—
HGD	<i>TP53</i> Arg248Gln	Liver transplantation	Suspicious	7	2	—
HGD	<i>KRAS</i> Gly12Asp <i>GNAS</i> Arg201Ser	Liver transplantation	Suspicious	5	4	—
HGD	<i>CDKN2A</i> His83Tyr <i>TP53</i> Arg175His <i>KRAS</i> Gly12Asp	Liver transplantation	Suspicious	4	6	—
HGD	No mutations	Liver transplantation	Suspicious	10	2	—
HGD ^a	No mutations	Liver transplantation	Negative	7	36	—
HGD	No mutations	Liver transplantation	Negative	11	20	—
LGD	<i>KRAS</i> Gln61His <i>GNAS</i> Arg201Cys	Liver transplantation	Suspicious	6	9	—
No biliary neoplasia	No mutations	Liver transplantation	Negative	13	47	—
No biliary neoplasia	No mutations	Liver transplantation	Negative	8	231	—
No biliary neoplasia	No mutations	Liver transplantation	Negative	12	16	—
No biliary neoplasia	No mutations	Liver transplantation	Negative	12	7	—
No biliary neoplasia	No mutations	Liver transplantation	Negative	11	19	—
No biliary neoplasia	No mutations	Liver transplantation	Negative	7	50	—
No biliary neoplasia	No mutations	Liver transplantation	Negative	13	26	—

Helsinki ERC score,^[19] serum CA19-9 levels (kU/L), brush cytology, NGS of brush cytology and histologically verified diagnosis. All detected mutations in successive brush samples are presented in this table. Histological type (small/large duct) and tumor localization are presented when available.

^aHGD in the perihilar and intrahepatic bile ducts after radiotherapy for suspected cholangiocarcinoma.

Abbreviations: CCA, cholangiocarcinoma; ERC score, Helsinki ERC score; GBC, gallbladder carcinoma; HGD, high-grade dysplasia; LGD, low-grade dysplasia; NGS, next-generation sequencing; NA, data not available.




FIGURE 3 Cytology and NGS results of the prospective cohort. NGS was considered positive if mutations in *TP53*, *CDKN2A*, *GNAS*, *BRAF*, *ATM*, or *FBXW7* were found. Abbreviations: CCA, cholangiocarcinoma; GBC, gallbladder carcinoma; HGD, high-grade dysplasia; LGD, low-grade dysplasia; NGS, next-generation sequencing.

Altered mutations after repeated NGS

In the first NGS analysis, 1 patient diagnosed with HGD of explanted liver tissue tested negative for mutations; however, a *GNAS* mutation was observed in the subsequent sample. In the next analysis, a *KRAS* mutation was detected.

Altered mutations among patients without histologically verified end points

Eight patients had variable alterations in *KRAS* or *GNAS*, and 1 had a *PIK3CA* mutation once during surveillance. All patients remained under surveillance without evidence of biliary neoplasia (Figure 4).

Sensitivity and specificity of NGS

The sensitivities and specificities of BC and NGS in the prospective cohort are shown in Table 4. In histologically verified cases, the sensitivity and specificity were 61% and 88% for BC and 67% and 88% for NGS, respectively. The combination of NGS and BC yielded the best performance, with sensitivity and specificity of 72% and 88%, respectively, for histologically verified patients. Overall, NGS combined with BC was superior to BC alone.

DISCUSSION

The risk of biliary dysplasia and CCA is high in patients with PSC, and early diagnosis of biliary neoplasia is challenging but important, as radical surgery or LT is a curative option only at an early stage. In a previous study, the sensitivity and specificity of NGS-based methods in the diagnosis of biliary neoplasia have been

shown to be increased compared to conventional biliary BC.^[24] In the present study, we report the NGS findings of biliary neoplasms in a retrospective analysis of histological samples from a cohort of patients with PSC and demonstrate the benefit of performing NGS on BC samples to detect biliary neoplasia. NGS combined with BC resulted in sensitivity and specificity of 72% and 88%, respectively, in histologically verified cases. This approach may increase the accuracy of BC combined with NGS to detect biliary neoplasia, which would enable early LT and, thus, markedly improve patient prognosis.

Several mutations associated with PSC-CCA, including *TP53*, *CDKN2A*, *FBXW7*, and *GNAS*, were observed in the prospective cohort, supporting the findings of earlier studies.^[7,24] Despite their location in the biliary tree, PSC-associated CCAs have a molecular profile of large duct CCAs.^[7] Furthermore, *KRAS*, *CDKN2A*, and *BRCA1* mutations are common^[25] in extrahepatic CCAs. In one patient with CCA in the prospective cohort, an *ATM* mutation was detected, which can occur in both intrahepatic and extrahepatic CCAs.^[26] In the current study, *RNF43* mutations were also observed in retrospective CCA and HGD samples, which is consistent with previous CCA studies.^[27] No *IDH* or *BAP1* mutations associated with intrahepatic CCA were detected.^[28] One patient in the retrospective cohort had several mutations, including *MSH6*. This may reflect a hypermutated phenotype due to mismatch repair defects, similar to a previous case of prostate adenocarcinoma.^[29]

Among patients with HGD, CCA-associated mutations, including *TP53*, *CDKN2A*, and *GNAS*, were detected in brush samples. Differentiating HGD from CCA using NGS is difficult because these conditions seem to share several mutations, although this does not pose a problem if early LT is an option. However, oncological treatments are needed if CCA develops, and when this occurs, LT becomes possible only in select cases.




FIGURE 4 Patients in the prospective cohort with altered next-generation sequencing results of follow-up brush samples. Brush cytology interpretation is also included. Abbreviations: CCA, cholangiocarcinoma; HGD, high-grade dysplasia; mo, months.

TABLE 4 Comparison of BC and NGS for detecting high-grade biliary neoplasia in patients with primary sclerosing cholangitis in the prospective cohort

Parameter	Sensitivity (95% CI)	Specificity (95% CI)	Positive predictive value (95% CI)	Negative predictive value (95% CI)
All patients (%)				
BC	61 (36–83)	92 (84–97)	65 (41–83)	91 (83–96)
NGS	67 (41–87)	97 (91–100)	86 (61–96)	93 (85–97)
BC or NGS	72 (47–90)	91 (83–96)	65 (43–82)	94 (86–97)
Histologically verified patients only (%)				
BC	61 (36–83)	88 (47–100)	92 (93–98)	50 (27–73)
NGS	67 (41–87)	88 (47–100)	92 (69–98)	54 (29–77)
BC or NGS	72 (47–90)	88 (47–100)	93 (71–99)	58 (32–81)

Abbreviations: BC, brush cytology; NGS, next-generation sequencing.

Although most patients with LGD in the retrospective cohort did not harbor any mutations, *TP53* and *SMAD4* mutations were observed in one LGD histological sample. In the prospective cohort, one patient with *KRAS* and *GNAS* mutations was diagnosed with LGD. Although the progression from LGD to HGD is probably gradual, these findings demonstrate that worrisome mutations may be present in histologically low-grade lesions. Thus, in cases of LGD suspicion by BC, NGS analysis should be performed in the next ERC.

In our study, *KRAS* mutations were observed without other mutations in 9 patients with no signs of biliary neoplasia during the surveillance period (12–44 months). In 1 patient, CCA was diagnosed with only a *KRAS* mutation in the brush sample, and 1 patient with a *KRAS* mutation in the brush sample was diagnosed with metastatic colorectal carcinoma. *KRAS* mutations are considered early cholangiocarcinogenesis events and may already be observed in cases of LGD.^[30] In another study, *KRAS* mutations were observed during cholangiocarcinogenesis.^[12] Without other evidence suggesting biliary neoplasia, we believe that *KRAS* mutations alone are an indication for continued surveillance, which is consistent with previous studies demonstrating that *KRAS* mutations may also occur in healthy individuals and patients with benign disease.^[31,32]

In gallbladder cancer, the same mutations are found in carcinomas and coexisting dysplasia or adenoma tissues, supporting the dysplasia-carcinoma sequence.^[33] In our study, no mutations were detected in biliary duct brush samples of the patient with GBC in the prospective cohort, probably reflecting the absence of cancer cells from the gallbladder in BC. This finding suggests that the value of BC and NGS is limited to diagnosing GBC, which requires imaging.

CCA is a feared complication of PSC, and ERC with BC has been used in the early diagnosis of CCA and to monitor patients with PSC in our unit since 2006. Regular imaging of patients with PSC is associated with improved survival, enabling earlier tumor detection even without MRI–magnetic resonance cholangiography features

suggestive of LGD/HGD.^[34] Initially, we performed ploidy analysis using DNA flow cytometry with BC;^[19,35] however, as no significant additive value was observed during dysplasia surveillance,^[15] we began to use NGS analysis as an ancillary test with BC in 2019. In our study, the BC results were sufficient in most cases; therefore, the additive value of NGS was limited. However, in some cases, NGS alterations occurred before suspicious BC findings were obtained. A suspicious NGS finding may identify a patient needing closer surveillance and imaging studies, leading to the possible early diagnosis of HGD or CCA.

In our study, CA19-9 was not sensitive in the detection of biliary neoplasia. Indeed, CA19-9 was elevated only in 3/10 patients with CCA and not in patients with dysplasia, which is in line with our previous results.^[15] While the CA19-9 level may be observed in CCA, it is not specific to malignancy; it may be elevated due to cholestasis, which is commonly seen in patients with PSC.^[36] Moreover, 40% of patients with PSC and elevated CA19-9 levels do not have CCA,^[37] and 10% of the general population does not express CA19-9.^[38] Thus, CA19-9 is neither sensitive nor specific for the screening and surveillance of CCA in patients with PSC. Recent American Association for the Study of Liver Diseases guidelines recommend that CCA and GBC surveillance should be performed annually and include abdominal imaging, with or without serum CA19-9.^[6]

Kamp et al^[12] showed that BC findings remained mostly the same in subsequent cases and were identical to NGS findings in histological samples. However, we observed some variation in the repeated samples, probably reflecting the cellularity and amount of inflammation in the samples. Our NGS detection rate for BC was 1%–2%; abundant inflammation or benign ductal cells in the sample may have obscured the neoplastic cell population. In 1 patient, the same *TP53* mutation remained in four subsequent BC samples. These findings emphasize that repeated sampling may increase the accuracy of BC detection of biliary neoplasia.

Cirrhosis is a common indication for LT in patients with PSC. In our center, approximately one-third of PSC-associated LTs are performed because of suspected biliary neoplasia.^[14] A patient is referred for the evaluation of LT in cases of repeated suspicion of HGD in BC; however, in cases of early CCA, LT may be indicated after oncological treatment. Patients with early perihilar CCA treated with neoadjuvant chemoradiotherapy and LT have a 5-year survival rate of up to 65%.^[39] Early identification of CCA is essential for curative treatment with neoadjuvant therapy and LT. Even in diffusely infiltrating CCA, where preoperative diagnosis is difficult, NGS of the bile can be used to preoperatively identify cancer-related mutations.^[40]

Genomic profiling of biliary tract cancers can identify potential targetable mutations.^[41] Occasionally, BC samples may be the only tissue source of prognostic/treatment markers if a histological sample is not obtained. Intraductal biopsies of the bile ducts can also be used to diagnose CCA or dysplasia, and NGS performed on bile duct biopsies reflects the resected tumor tissue,^[42] although the diagnostic accuracy of cholangioscopy for indeterminate biliary strictures was inferior to that of BC.^[43] In our prospective study population, cholangioscopy (Spy-Glass, Boston Scientific, MA) was performed in 5 patients. Four of the patients had HGD or suspicion of CCA in the biopsy, and all these patients were diagnosed with CCA. One patient had benign biopsy results in cholangioscopy, and BC and NGS were negative. This patient did not have any signs of malignancy during follow-up.

The strength of this study is that it included a well-defined cohort of patients who underwent structured surveillance. In our institute, BC is performed in patients with PSC by brushing the intrahepatic and extra bile ducts as widely as possible, regardless of the dominant stricture. However, as the number of patients with histologically verified end points was low, further studies are needed to evaluate the value of the molecular analysis of BC. In the retrospective cohort, the quantity and quality of DNA in the archived samples was a limiting factor in NGS analyses. Moreover, the rate of CCA development remains unclear. With NGS, the early diagnosis of CCA or HGD may be possible.

In conclusion, NGS is an important addition to conventional BC for the diagnosis of biliary neoplasia in BC. Mutations in *KRAS*, *TP53*, *CDKN2A*, and *GNAS* were observed in brush samples from patients with HGD or CCA, whereas mutations in *FBXW7*, *ATM*, and *BRAF* were only seen in brush samples from patients with CCA.

AUTHOR CONTRIBUTIONS

Johanna Arola, Martti Färkkilä, and Sonja Boyd: conceived the study. Johanna Arola and Martti

Färkkilä: supervised this study. Sonja Boyd, Soili Kytölä, and Martti Färkkilä: collected the data. Soili Kytölä, Taru Mustamäki, and Laura Lahtinen: performed NGS analyses. Sonja Boyd: wrote the first draft of the manuscript. Tommi Rantapero, Thomas Liuksiala, and Soili Kytölä: performed bioinformatics analysis. Tommi Rantapero, Sonja Boyd, and Thomas Liuksiala: performed the statistical analyses. All the authors critically revised the manuscript and approved the final draft.

FUNDING INFORMATION

This study was financially supported by The Finnish Association of Transplantational Surgery, Maud Kuistila Memorial Foundation, and the HUH Diagnostic Centre, Competitive Research Funding of HUH. Open access funded by Helsinki University Library.

CONFLICTS OF INTEREST

Nelli Sjöblom consults for Aiforia Technologies. Teijo Kuopio advises Amgen and received grants from Pfizer. The remaining authors have no conflicts to report.

ORCID

Sonja Boyd  <https://orcid.org/0000-0002-4199-3008>
 Taru Mustamäki  <https://orcid.org/0009-0000-6661-0483>
 Nelli Sjöblom  <https://orcid.org/0000-0002-3360-6645>
 Arno Nordin  <https://orcid.org/0000-0002-5446-0972>
 Andrea Tenca  <https://orcid.org/0000-0002-9064-0612>
 Tommi Rantapero  <https://orcid.org/0000-0002-0550-3075>
 Thomas Liuksiala  <https://orcid.org/0000-0003-1148-5405>
 Laura Lahtinen  <https://orcid.org/0000-0001-7559-2168>
 Teijo Kuopio  <https://orcid.org/0000-0003-3503-4094>
 Soili Kytölä  <https://orcid.org/0000-0002-4477-0942>
 Martti Färkkilä  <https://orcid.org/0000-0002-0250-8559>
 Johanna Arola  <https://orcid.org/0000-0003-3865-5507>

REFERENCES

1. Barner-Rasmussen N, Pukkala E, Jussila A, Färkkilä M. Epidemiology, risk of malignancy and patient survival in primary sclerosing cholangitis: A population-based study in Finland. *Scand J Gastroenterol*. 2020;55:74–81.
2. Bergquist A, Ekblom A, Olsson R, Kornfeldt D, Löf L, Danielsson A, et al. Hepatic and extra-hepatic malignancies in primary sclerosing cholangitis. *J Hepatol*. 2002;36:321–7.
3. Claessen MM, Vleggaar FP, Tytgat KM, Siersema PD, van Buuren HR. High lifetime risk of cancer in primary sclerosing cholangitis. *J Hepatol*. 2009;50:158–64.
4. Fevery J, Henckaerts L, Van Oirbeek R, Vermeire S, Rutgeerts P, Nevens F, et al. Malignancies and mortality in 200 patients

- with primary sclerosing cholangitis: A long-term single-centre study. *Liver Int.* 2012;32:214–22.
5. Lewis JT, Talwalkar JA, Rosen CB, Smyrk TC, Abraham SC. Precancerous bile duct pathology in end-stage primary sclerosing cholangitis, with and without cholangiocarcinoma. *Am J Surg Pathol.* 2010;34:27–34.
 6. Bowlus CL, Arrivé L, Bergquist A, Deneau M, Forman L, Ilyas SI, et al. AASLD practice guidance on primary sclerosing cholangitis and cholangiocarcinoma. *Hepatology.* 2023;77:659–702.
 7. Goeppert B, Folseraas T, Roessler S, Kloor M, Volckmar AL, Endris V, et al. Genomic characterization of cholangiocarcinoma in primary sclerosing cholangitis reveals therapeutic opportunities. *Hepatology.* 2020;72:1253–66.
 8. Nakanuma Y, Kakuda Y. Pathologic classification of cholangiocarcinoma: New concepts. *Best Pract Res Clin Gastroenterol.* 2015;29:277–93.
 9. Kendall T, Verheij J, Gaudio E, Evert M, Guido M, Goeppert B, et al. Anatomical, histomorphological and molecular classification of cholangiocarcinoma. *Liver Int.* 2019;39(suppl 1):7–18.
 10. Nakamura H, Arai Y, Totoki Y, Shiota T, Elzawahry A, Kato M, et al. Genomic spectra of biliary tract cancer. *Nat Genet.* 2015;47:1003–10.
 11. Putra J, de Abreu FB, Peterson JD, Pipas JM, Mody K, Amos CI, et al. Molecular profiling of intrahepatic and extra-hepatic cholangiocarcinoma using next generation sequencing. *Exp Mol Pathol.* 2015;99:240–4.
 12. Kamp EJ, Dinjens WN, Doukas M, van Marion R, Verheij J, Ponsioen CY, et al. Genetic alterations during the neoplastic cascade towards cholangiocarcinoma in primary sclerosing cholangitis. *J Pathol.* 2022;258:227–35.
 13. Azad AI, Rosen CB, Taner T, Heimbach JK, Gores GJ. Selected patients with unresectable perihilar cholangiocarcinoma (pCCA) derive long-term benefit from liver transplantation. *Cancers (Basel).* 2020;12:3157.
 14. Vannas MJ, Boyd S, Färkkilä MA, Arola J, Isoniemi H. Value of brush cytology for optimal timing of liver transplantation in primary sclerosing cholangitis. *Liver Int.* 2017;37:735–42.
 15. Boyd S, Mustonen H, Tenca A, Jokelainen K, Arola J, Färkkilä MA. Surveillance of primary sclerosing cholangitis with ERC and brush cytology: risk factors for cholangiocarcinoma. *Scand J Gastroenterol.* 2017;52:242–9.
 16. Trikudanathan G, Navaneethan U, Njei B, Vargo JJ, Parsi MA. Diagnostic yield of bile duct brushings for cholangiocarcinoma in primary sclerosing cholangitis: A systematic review and meta-analysis. *Gastrointest Endosc.* 2014;79:783–9.
 17. Singhi AD, Nikiforova MN, Chennat J, Papachristou GI, Khalid A, Rabinovitz M, et al. Integrating next-generation sequencing to endoscopic retrograde cholangiopancreatography (ERCP)-obtained biliary specimens improves the detection and management of patients with malignant bile duct strictures. *Gut.* 2020;69:52–61.
 18. Arechederra M, Rullán M, Amat I, Oyon D, Zabalza L, Elizalde M, et al. Next-generation sequencing of bile cell-free DNA for the early detection of patients with malignant biliary strictures. *Gut.* 2022;71:1141–51.
 19. Boyd S, Tenca A, Jokelainen K, Mustonen H, Krogerus L, Arola J, et al. Screening primary sclerosing cholangitis and biliary dysplasia with endoscopic retrograde cholangiography and brush cytology: Risk factors for biliary neoplasia. *Endoscopy.* 2016;48:432–9.
 20. McLaren W, Gil L, Hunt SE, Riat HS, Ritchie GR, Thormann A, et al. The Ensembl variant effect predictor. *Genome Biol.* 2016;17:122.
 21. Masica DL, Douville C, Tokheim C, Bhattacharya R, Kim R, Moad K, et al. CRAVAT 4: Cancer-related analysis of variants toolkit. *Cancer Res.* 2017;77:e35–8.
 22. Mayakonda A, Lin DC, Assenov Y, Plass C, Koeffler HP. Maftools: Efficient and comprehensive analysis of somatic variants in cancer. *Genome Res.* 2018;28:1747–56.
 23. R Core Team. R: A Language and Environment for Statistical Computing The R Foundation for Statistical Computing, Vienna, Austria. 2023. <https://www.R-project.org/>
 24. Kamp EJCA, Dinjens WNM, Van Velthuysen MF, de Jonge PJF, Bruno MJ, Peppelenbosch MP, et al. Next-generation sequencing mutation analysis on biliary brush cytology for differentiation of benign and malignant strictures in primary sclerosing cholangitis. *Gastrointest Endosc.* 2023;97:456–465.e6.
 25. Weinberg BA, Xiu J, Lindberg MR, Shields AF, Hwang JJ, Poorman K, et al. Molecular profiling of biliary cancers reveals distinct molecular alterations and potential therapeutic targets. *J Gastrointest Oncol.* 2019;10:652–2.
 26. Zheng Y, Qin Y, Gong W, Li H, Li B, Wang Y, et al. Specific genomic alterations and prognostic analysis of perihilar cholangiocarcinoma and distal cholangiocarcinoma. *J Gastrointest Oncol.* 2021;12:2631–42.
 27. Kendre G, Murugesan K, Brummer T, Segatto O, Saborowski A, Vogel A. Charting co-mutation patterns associated with actionable drivers in intrahepatic cholangiocarcinoma. *J Hepatol.* 2023;78:614–26.
 28. Moeini A, Sia D, Bardeesy N, Mazzaferro V, Llovet JM. Molecular pathogenesis and targeted therapies for intrahepatic cholangiocarcinoma. *Clin Cancer Res.* 2016;15:291–300.
 29. Pritchard CC, Morrissey C, Kumar A, Zhang X, Smith C, Coleman I, et al. Complex MSH2 and MSH6 mutations in hypermutated microsatellite unstable advanced prostate cancer. *Nat Commun.* 2014;5:4988.
 30. Hsu M, Sasaki M, Igarashi S, Sato Y, Nakanuma Y. KRAS and GNAS mutations and p53 overexpression in biliary intraepithelial neoplasia and intrahepatic cholangiocarcinomas. *Cancer.* 2013;119:1669–74; [Epub 2013 January 18]. Erratum in: *Cancer.* 2013;119:1669–74.
 31. Yang S, Che SP, Kurywchak P, Tavormina JL, Gansmo LB, Correa de Sampaio P, et al. Detection of mutant KRAS and TP53 DNA in circulating exosomes from healthy individuals and patients with pancreatic cancer. *Cancer Biol Ther.* 2017;18:158–65.
 32. Wang ZY, Ding XQ, Zhu H, Wang RX, Pan XR, Tong JH. KRAS mutant allele fraction in circulating cell-free DNA correlates with clinical stage in pancreatic cancer patients. *Front Oncol.* 2019;9:1295.
 33. Lin J, Peng X, Dong K, Long J, Guo X, Li H, et al. Genomic characterization of co-existing neoplasia and carcinoma lesions reveals distinct evolutionary paths of gallbladder cancer. *Nat Commun.* 2021;12:4753.
 34. Bergquist A, Weismüller TJ, Levy C, Rupp C, Joshi D, Nayagam JS, et al. Impact on follow-up strategies in patients with primary sclerosing cholangitis. *Liver Int.* 2023;43:127–38.
 35. Halme L, Arola J, Numminen K, Krogerus L, Mäkisalo H, Färkkilä M. Biliary dysplasia in patients with primary sclerosing cholangitis: Additional value of DNA ploidy. *Liver Int.* 2012;32:783–9.
 36. Tsen A, Barbara M, Rosenkranz L. Dilemma of elevated CA 19–9 in biliary pathology. *Pancreatol.* 2018;18:862–7.
 37. Sinakos E, Saenger AK, Keach J, Kim WR, Lindor KD. Many patients with primary sclerosing cholangitis and increased serum levels of carbohydrate antigen 19–9 do not have cholangiocarcinoma. *Clin Gastroenterol Hepatol.* 2011;9:434–9.
 38. Parra-Robert M, Santos VM, Canis SM, Pla XF, Fradera JMA, Porto RM. Relationship between CA 19.9 and the Lewis phenotype: options to improve diagnostic efficiency. *Anticancer Res.* 2018;38:5883–8.
 39. Darwish Murad S, Kim WR, Harnois DM, Douglas DD, Burton J, Kulik LM, et al. Efficacy of neoadjuvant chemoradiation, followed

by liver transplantation, for perihilar cholangiocarcinoma at 12 US centers. *Gastroenterology*. 2012;143:88–98.e3.

40. Lee CH, Wang HE, Seo SY, Kim SH, Kim IH, Kim SW, et al. Cancer related gene alterations can be detected with next-generation sequencing analysis of bile in diffusely infiltrating type cholangiocarcinoma. *Exp Mol Pathol*. 2016;101:150–6.
41. Jain A, Kwong LN, Javle M. Genomic profiling of biliary tract cancers and implications for clinical practice. *Curr Treat Options Oncol*. 2016;17:58.
42. Bankov K, Döring C, Schneider M, Hartmann S, Winkelmann R, Albert JG, et al. Sequencing of intraductal biopsies is feasible and potentially impacts clinical management of patients with indeterminate biliary stricture and cholangiocarcinoma. *Clin Transl Gastroenterol*. 2018;9:151.
43. de Vries AB, van der Heide F, Ter Steege RWF, Koornstra JJ, Buddingh KT, Gouw ASH, et al. Limited diagnostic accuracy and

clinical impact of single-operator peroral cholangioscopy for indeterminate biliary strictures. *Endoscopy*. 2020;52:107–4.

How to cite this article: Boyd S, Mustamäki T, Sjöblom N, Nordin A, Tenca A, Jokelainen K, et al. NGS of brush cytology samples improves the detection of high-grade dysplasia and cholangiocarcinoma in patients with primary sclerosing cholangitis: A retrospective and prospective study. *Hepatol Commun*. 2024;8:e0415. <https://doi.org/10.1097/HC9.0000000000000415>