

## FREE COMMUNICATIONS 2

[FC6]  
**DISCRIMINATING BASAL CELL CARCINOMA  
 AND BOWEN'S DISEASE WITH NOVEL  
 HYPERSPECTRAL IMAGING SYSTEM AND  
 CONVOLUTIONAL NEURAL NETWORKS**

*Mari Salmivuori<sup>1</sup>, Vivian Lindholm<sup>2</sup>, Leevi Annala<sup>3</sup>, Anna-Maria Raita-Hakola<sup>3</sup>, Leila Jeskanen<sup>4</sup>, Ilkka Pölönen<sup>3</sup>, Sari Koskenmies<sup>5</sup>, Sari Pitkänen<sup>6</sup>, Kirsi Isoherranen<sup>7</sup>, Annamari Ranki<sup>8</sup>*

<sup>1</sup>Helsinki University Central Hospital, Helsinki University Hospital, Skin and Allergy Hospital, Department of Dermatology, Allergology and Venereology, Helsinki, Finland <sup>2</sup>Helsinki University Hospital, University of Helsinki, Skin and Allergy Hospital, Helsinki, Finland <sup>3</sup>University of Jyväskylä, University of Jyväskylä, Faculty of Information Technology, Jyväskylä, Finland <sup>4</sup>Helsinki University Central Hospital, Helsinki University Hospital, Department of Dermatology, Allergology and Venereology, Helsinki, Finland <sup>5</sup>Helsinki University Hospital, Helsinki University Hospital and University of Helsinki, Department of Dermatology, Helsinki, Finland <sup>6</sup>University Hospital of Helsinki, Helsinki University Hospital, Dermatology Outpatient Clinic, Hus, Finland <sup>7</sup>University Central Hospital of Helsinki, Helsinki University Hospital, Dermatocurgery, Helsinki, Finland <sup>8</sup>Helsinki University Central Hospital, Helsinki University Hospital, Skin and Allergy Hospital, Helsinki, Finland

**Purpose:** Skin cancers are the commonest cancer type in the world. With non-invasive imaging technologies it is possible to

make an early diagnosis and thus reduce the burden of the disease. Hyperspectral imaging (HSI) is a relatively fast non-invasive imaging method with large field of view and combining it to machine learning and convolutional neural networks (CNN) enables interpretation of the data independent from the user.

**Methods:** In total, 119 lesions were analysed, with 27 intradermal nevi (ID), 22 basal cell carcinomas (BCC), 40 seborrheic keratoses (SK) and 30 Bowen's disease (BD). All lesions were imaged with our novel HSI-system, which provides 3D data of the object through photometric stereo imaging and specific depth data of each wavelength, additionally to the hyperspectral data. Histopathological samples were obtained to confirm the diagnosis. A CNN was trained with the leave-one-out cross validation method. The images were classified with pixel-wise and majority voting methods.

**Results:** In the majority voting, classifying of BCC, ID and healthy skin the sensitivity was 89%, specificity 94% and positive predictive value 90%. For BD, SK and healthy skin the results were respectively 87%, 92% and 87%. Pixelwise analysis provided map-like presentations of the results (Figure 1).

**Conclusions:** This pilot study using a novel non-invasive HSI-CNN system shows a good sensitivity, not compromised by low specificity, and proves the HSI-CNN camera useful in discriminating malignant from benign, in common, mainly non-pigmented skin cancer types. Larger multicentre trials are warranted.

Figure 1A: An example of the pixel-wise classification of an intradermal nevus

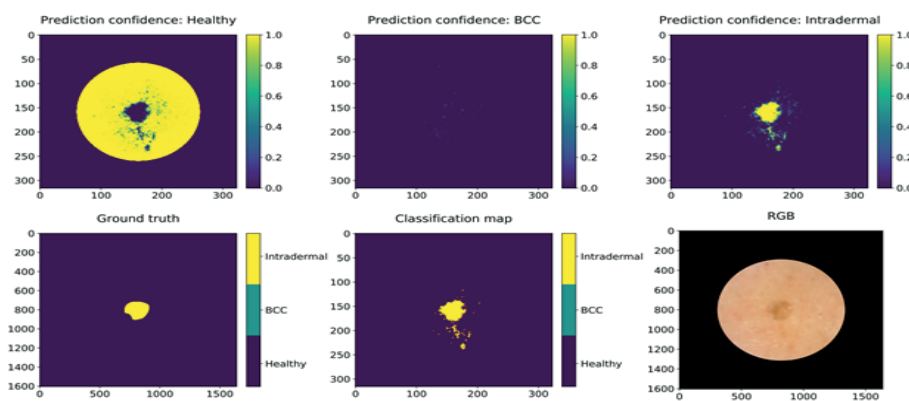


Figure 1A: An example of the pixel-wise classification of a basal cell carcinoma

