

**This is a self-archived version of an original article. This version may differ from the original in pagination and typographic details.**

**Author(s):** Lindholm, Vivian; Raita-Hakola, Anna-Maria; Annala, Leevi; Salmivuori, Mari; Jeskanen, Leila; Koskenmies, Sari; Pitkänen, Sari; Saari, Heikki; Pölönen, Ilkka; Isoherranen, Kirsi; Ranki, Annamari

**Title:** Differentiating Malignant from Benign for Melanocytic and Non-melanocytic Skin Tumors : A Pilot Study on Hyperspectral Imaging and Convolutional Neural Networks

**Year:** 2022

**Version:** Published version

**Copyright:** © the Authors, 2022.

**Rights:** CC BY-NC 4.0

**Rights url:** <https://creativecommons.org/licenses/by-nc/4.0/>

**Please cite the original version:**

Lindholm, V., Raita-Hakola, A.-M., Annala, L., Salmivuori, M., Jeskanen, L., Koskenmies, S., Pitkänen, S., Saari, H., Pölönen, I., Isoherranen, K., & Ranki, A. (2022). Differentiating Malignant from Benign for Melanocytic and Non-melanocytic Skin Tumors : A Pilot Study on Hyperspectral Imaging and Convolutional Neural Networks. In Abstracts from 35th Congress of Nordic Dermatology and Venereology (pp. 51). Society for Publication of Acta Dermato-Venereologica. Acta Dermato-Venereologica, Suppl 222.

<https://medicaljournalssweden.se/actadv/issue/view/159>

[P73]

### AN ECONOMIC ANALYSIS OF TELEDERMOSCOPY IN THE REGION OF SOUTHERN DENMARK

Tine Vestergaard<sup>1</sup>, Merethe Andersen<sup>2</sup>, Kristian Kidholm<sup>3</sup>

<sup>1</sup>Odense University Hospital, Department of Dermatology and Allergy Centre, Odense C, Denmark, <sup>2</sup>University of Southern Denmark, Research Unit of General Practice, <sup>3</sup>Odense University Hospital, Centre for Innovative Medical Technology

**Purpose:** To calculate and compare costs of teledermoscopy and standard care in the form of face-to-face evaluation by a dermatologist of suspected skin cancers.

**Methods:** In 2018, 48 general practices in the region of Southern Denmark included 519 adults with suspected skin cancers and referred them to a specialized (university hospital) skin cancer clinic for teledermoscopic and face-to-face (FTF) evaluation. This cost-minimization analysis was based on detailed information obtained in a diagnostic accuracy study and a patient questionnaire study on teledermoscopy, supplemented with publicly available data on e.g. standard reimbursement rates for health care services. Investment costs, costs in general practice, hospital associated costs and patient costs were included to calculate the average cost per patient episode. Two independent sets of data on teledermoscopy (TDS1 + TDS2) and one data set on FTF evaluation were available from the diagnostic accuracy study. Sensitivity analyses were performed for six different clinically relevant scenarios.

**Results:** The total cost per patient episode was €17.2 to €23.1 higher for teledermoscopy than for standard care. (FTF: €620.7 (95% CI €594.8-646.5), TDS1: €643.8 (95% CI €613.5-674.1)  $p=0.009$ , TDS2: €637.9 (95% CI €607.0-668.7)  $p=0.08$ ) However, patient costs and hospital associated costs were significantly reduced.

**Conclusions:** Benefits to patients may warrant the slightly higher costs of teledermoscopy. Sensitivity analyses indicated that number of preventable face-to-face evaluations and the distance to the dermatologist were the two factors that influenced costs the most. This is relevant to consider when implementing teledermoscopy in clinical practice.

[P74]

### DIFFERENTIATING MALIGNANT FROM BENIGN FOR MELANOCYTIC AND NON-MELANOCYTIC SKIN TUMORS- A PILOT STUDY ON HYPERSPECTRAL IMAGING AND CONVOLUTIONAL NEURAL NETWORKS

Vivian Lindholm<sup>1</sup>, Anna-Maria Raita-Hakola<sup>2</sup>, Leevi Annala<sup>2</sup>, Mari Salmivuori<sup>3</sup>, Leila Jeskanen<sup>4</sup>, Sari Koskenmies<sup>5</sup>, Sari Pitkä-

nen<sup>6</sup>, Heikki Saari<sup>7</sup>, Ilkka Pölönen<sup>2</sup>, Kirsi Isoherranen<sup>8</sup>, Annamari Ranki<sup>1</sup>

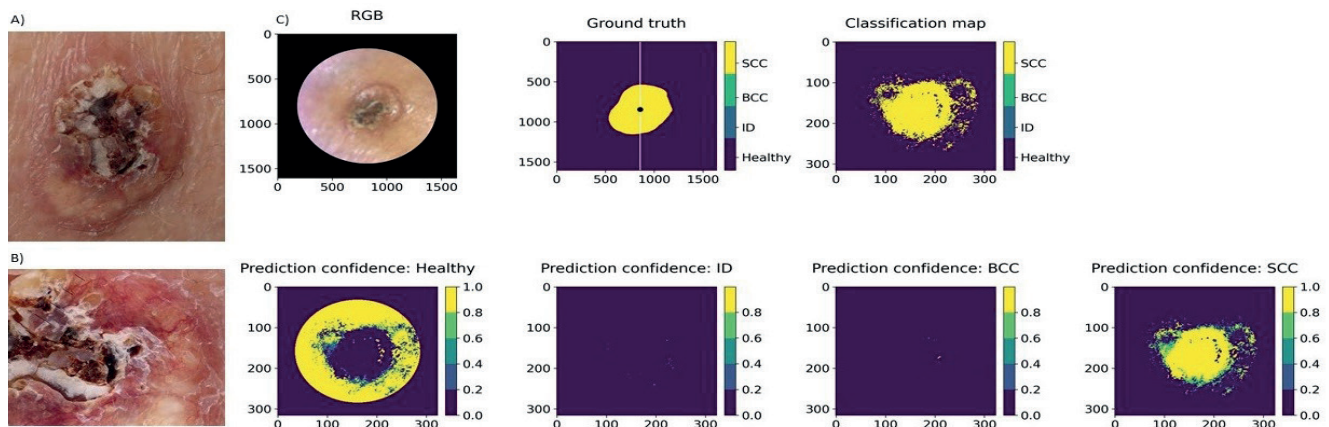
<sup>1</sup>Helsinki University Hospital, University of Helsinki, Skin and Allergy Hospital, Helsinki, Finland, <sup>2</sup>University of Jyväskylä, University of Jyväskylä, Faculty of Information Technology, Jyväskylä, Finland, <sup>3</sup>Helsinki University Central Hospital, Helsinki University Hospital, Skin and Allergy Hospital, Department of Dermatology, Allergology and Venereology, Helsinki, Finland, <sup>4</sup>Helsinki University Central Hospital, Helsinki University Hospital, Department of Dermatology, Allergology and Venereology, Helsinki, Finland, <sup>5</sup>Helsinki University Hospital, Helsinki University Hospital and University of Helsinki, Department of Dermatology, Helsinki, Finland, <sup>6</sup>University Hospital of Helsinki, Helsinki University Hospital, Dermatology Outpatient Clinic, Hus, Finland, <sup>7</sup>Vtt Technical Research Centre of Finland Ltd, Espoo, Finland, <sup>8</sup>University Central Hospital of Helsinki, Helsinki University Hospital, Dermatosurgery, Helsinki, Finland

**Purpose:** Several optical imaging techniques have been developed to ease the burden of skin cancer disease on our health care system. Hyperspectral (HS) images identify biological tissues by their diffuse reflected spectra.

**Methods:** In this second part of a three-phased pilot study, we used a novel hand-held SICSURFIS Spectral Imager with an adaptable field of view and target-wise selectable wavelength channels, developed to provide detailed spectral and spatial data on lesions of complex surfaces. 42 lesions were studied: 7 melanomas, 13 pigmented and 7 intradermal nevi, 10 basal cell and 5 squamous cell carcinomas. The HS images (33 wavelengths, 477-891 nm) provided photometric data through individually controlled illumination modules, enabling the convolutional networks to utilise both spectral, spatial, and skin surface models for the analyses. All lesions were excised for histopathological analyses.

**Results:** The pixel-wise analysis provided map-like images (Figure 1) and classified melanocytic lesions with a sensitivity and specificity of 87% and 93% and correspondingly for non-melanocytic lesions, 79% and 91%. The majority voting analysis, providing the most probable lesion diagnosis, diagnosed 41 of 42 lesions correctly.

**Conclusions:** This pilot study indicates that this non-invasive hyperspectral imaging system with shape and depth data is feasible in differentiating melanocytic and non-melanocytic skin tumours even of complex skin surfaces. These promising results support the results of our first pilot study; however, need to be verified in a broader sampled material.



**Figure 1.** A A) clinical and B) dermoscopy image and C) the classification map of a 15mm SCC on the leg. Clinically this lesion could be either a basal cell carcinoma (BCC) or a squamous cell carcinoma (SCC), but it was correctly classified as a SCC by the SICSURFIS system. ID = intradermal nevus. RGB=red-green-blue.