

This is a self-archived version of an original article. This version may differ from the original in pagination and typographic details.

Author(s): Hutz, Bettina; Degens, Hans; Korhonen, Marko T.

Title: Oldies, but goldies : preserved morphology and stability of antigenic determinants in decades-old cryosections of human m. vastus lateralis

Year: 2024

Version: Published version

Copyright: © 2024 The Authors. Journal of Anatomy published by John Wiley & Sons Ltd on b

Rights: CC BY-NC-ND 4.0

Rights url: <https://creativecommons.org/licenses/by-nc-nd/4.0/>

Please cite the original version:

Hutz, B., Degens, H., & Korhonen, M. T. (2024). Oldies, but goldies : preserved morphology and stability of antigenic determinants in decades-old cryosections of human m. vastus lateralis. *Journal of Anatomy*, Early View. <https://doi.org/10.1111/joa.14003>

Oldies, but goldies—preserved morphology and stability of antigenic determinants in decades-old cryosections of human *m. vastus lateralis*

Bettina Hutz¹ | Hans Degens^{2,3}  | Marko T. Korhonen⁴ 

¹Faculty of Sport and Health Sciences, University of Jyväskylä, Jyväskylä, Finland

²Department of Life Sciences, Manchester Metropolitan University, Manchester, UK

³Institute of Sport Science and Innovations, Lithuanian Sports University, Kaunas, Lithuania

⁴Gerontology Research Center, Faculty of Sport and Health Sciences, University of Jyväskylä, Jyväskylä, Finland

Correspondence

Bettina Hutz, Faculty of Sport and Health Sciences, University of Jyväskylä, Finland.
Email: bettina.b.hutz@ju.fi

Abstract

Fibre typing by immunohistochemistry on cryosections from human skeletal muscle biopsies is an essential tool in the diagnosis and research of muscular diseases, ageing, and responses to exercise training and disuse. Preserving a good quality in these frozen specimens can be challenging especially if they are stored for longer periods before histological processing, which is often the case in studies with a large number of test subjects and/or repeated sampling separated by multiple years. We demonstrate in this article that both, the morphology and reactivity of epitopes to myosin heavy chain isoforms and dystrophin are well preserved in up to 18-year-stored unfixed and unstained cryosections of human *m. vastus lateralis* ($n = 241$). Any variation in staining intensity between samples was unrelated to the age of the biopsy donor or the storage period of the unstained cryosections, and in all cases, the obtained images were appropriate for image analysis, such as the determination of the fibre type composition and the fibre cross-sectional area, and quantitative analysis of muscle capillarisation.

KEYWORDS

epitope preservation, frozen sections, long term storage

1 | INTRODUCTION

The method to obtain percutaneous muscle biopsies has been invented more than 150 years ago by Duchenne (1868). The needle design and sampling technique was modified by Bergström in the 1960s (Bergström, 1962) and has remained largely unchanged (Edwards, 1971; Edwards et al., 1980). Followed by immediate snap freezing and histological processing, muscle biopsies have become an indispensable tool for medical diagnosis and research. For instance, histological examination of muscle biopsies can reveal unusual variations in fibre sizes and atrophy that are

characteristic of muscle myopathies (e.g. Nowak & Reyes, 2008) and splitting of muscle fibres typical for muscle dystrophies (e.g. Walters & Baborie, 2020). In research, muscle biopsies can provide insight into the type of muscular changes that occur for example during sarcopenia, the age-related loss of muscle mass and functionality, and hypertrophy in response to resistance training or overload (e.g. Frontera et al., 1988). The freezing and processing of human or rodent muscle tissue come with challenges, such as the development of freezing artefacts (Sjöström, 1975), and suboptimal storage conditions that may lead to the deterioration of morphology and epitopes. In contrast to clinical diagnosis, it

This is an open access article under the terms of the [Creative Commons Attribution-NonCommercial-NoDerivs](https://creativecommons.org/licenses/by-nc-nd/4.0/) License, which permits use and distribution in any medium, provided the original work is properly cited, the use is non-commercial and no modifications or adaptations are made.

© 2024 The Authors. *Journal of Anatomy* published by John Wiley & Sons Ltd on behalf of Anatomical Society.

is common practice in research to first collect the full number of samples within a study before advancing with further procedures. Although it is commonly believed that unstained cryosections may become unusable after extensive storage periods, we are not aware of any studies that tested systematically whether cryosections stored for more than 15 years do indeed exhibit a diminished immunofluorescence (IF) labelling and morphology if optimal sampling and storage conditions are met. Therefore, the aim of our work was to determine whether the fibre type composition, fibre cross-sectional area (FCSA), and quantitative measures of muscle capillarisation can still be determined in cryosections of human *m. vastus lateralis*, which have been stored at -80°C for 9 and 18 years (longitudinal study design).

Earlier, we have used myosin ATPase histochemistry to determine fibre types, but an equally reliable but more modern technique is immunofluorescent (IF) labelling of myosin heavy chain (MyHC) isoforms (Murach et al., 2019; Song et al., 2020), which we have chosen here because it allows simultaneous labelling for additional targets in the same section, such as the sarcolemma and capillaries. We demonstrate that cryosections, which have been stored at -80°C for up to 18 years, can not only still be labelled with antibodies against MyHC types, dystrophin, and a conjugated marker for lectin, but these epitopes appear not to be affected by prolonged storage periods and hence even 18 years of storage does not diminish the suitability of cryosections to assess muscle morphology, capillarisation and fibre type composition.

2 | METHODS

2.1 | Biopsies and cryosections

We have obtained 241 Bergström needle biopsies of the *m. vastus lateralis* from 161 men (athletes aged 18–95 years and non-athletic controls) in the years 2002, 2003 and 2012 (incl. 10-year follow-up) (Table 1). As described earlier, a transversal piece of the biopsies was chosen for histological examination and attached with O.C.T. freezing compound (Sakura Finetek, USA) to a small cork piece, frozen in isopentane chilled with liquid nitrogen to a temperature of -160°C (Korhonen et al., 2006). The cork piece with the attached muscle was wrapped tightly in aluminium foil and stored for a maximum of one year at -80°C until cryo-sectioning. The 10- μm -thick cryosections were produced with a cryostat (Leica CM 3000) at -24°C , air-dried

for approximately 30 min and at least 6 slides with 3 cryosections each per biopsy were stored unfixed and unstained in plastic slide boxes at -80°C for 9 and 18 years before IF labelling. As a control, we have taken a biopsy of the *m. vastus lateralis* of 5 healthy donors (3 men and 2 women, age 26–51 years) of which the sample was stored for less than 6 months at -80°C before cutting 8- μm cryosections. IF labelling was done after 2 weeks of storage at -80°C .

2.2 | Triple, parallel IF labelling

The cryosections were removed from the -80°C freezer, air dried for 10 min, shortly rinsed with phosphate-buffered saline and stained as described in Table 2. For the determination of MyHC isoform types, monoclonal antibodies (Developmental Studies Hybridoma Bank, USA) against BA-D5 (MyHC type I), BF-35 (all MyHC type II but IIx) were used in a cocktail also containing a polyclonal antibody (ab15277, Abcam, UK) against dystrophin. The primary and secondary antibodies were applied in a volume of 50 μL and their specifications and dilutions are given in Table 3. We also performed negative controls by omitting the primary antibodies on cryosections of fresh biopsies.

2.3 | Capillary staining

For the detection of the capillaries, *Ulex europaeus* agglutinin I (UEA1, DyLight™ 649, DL-1068-1, Vector Laboratories, USA) was added to the secondary antibody cocktail in a dilution of 1:200.

2.4 | Imaging

Microscopic images were obtained with a Zeiss LSM 700 confocal microscope and a 10x objective. The image acquisition parameters were adjusted individually for each image to achieve optimal intensity and contrast while avoiding over- and underexposed areas. To do so, we used the range indicator tool in the Zeiss ZEN software (Germany) to obtain signal intensities as close as possible to the upper range of non-overexposure.

3 | RESULTS

Clear and distinct fluorescent signals were acquired from all proteins of interest in all cryosections that were independent of storage duration at -80°C or age of the biopsy donor before IF labelling (Figure 1). In some cases, the intensity of the four fluorescent signals was weaker than in most of the images, but this could be accommodated during image acquisition. The morphology of all cryosections stored for 18 and 9 years at -80°C was well preserved, indicated by a focused and smooth dystrophin signal surrounding each fibre. The signals for the two MyHC-isoforms

TABLE 1 Overview of the sampling, storage and processing times of the biopsies from human *m. vastus lateralis*.

Biopsy (year)	n	Sectioning (year)	Storage of cryosection at -80°C
2002	80	2003	18 years
2003	64	2003	18 years
2012	97	2012	9 years
2020	5	2021	< 6 months

TABLE 2 Immunofluorescence staining protocol.

Step	Solution	Duration	Temperature
1. Fixation	Methanol	10 min	-20°C
2. Washing	PBS	5 min	RT
3. Permeabilisation	0.2% Tween 20 in PBS	10 min	RT
4. Washing	PBS	5 min	RT
5. Blocking	10% NGS in PBS	1 h	RT
6. Primary antibody cocktail	10% NGS in PBS	1 h	RT
7. Washing	PBS	3×5 min	RT
8. Secondary antibody cocktail	PBS	1 h	RT (in the dark)
9. Washing	PBS	3×5 min	RT (in the dark)
10. Mounting	ProLong(TM)Diamond		

Abbreviations: NGS, normal goat serum; PBS, phosphate-buffer saline; RT, room temperature.

TABLE 3 Specifications and dilutions of the primary and secondary antibodies.

Primary antibodies					
Name	IgG isoform	Manufacturer	Cat #	RRID	Dilution
BA-D5	Mouse IgG2b	DSHB	BA-D5-s	AB_2235587	1:40
BF-35	Mouse IgG1	DSHB	BF-35-s	AB_2274680	1:40
Dystrophin	Rabbit IgG	Abcam	ab15277	AB_301813	1:200
Secondary antibodies					
Host & target IgG	Conjugate	Manufacturer	Cat #	RRID	Dilution
Goat anti-mouse IgG2b	AlexaFluor™ 405	Jackson ImmunoResearch	115-475-207	AB_2338801	1:500
Goat anti-mouse IgG1	AlexaFluor™ 488	Thermo Fisher Scientific	A-21121	AB_2535764	1:500
Goat anti-rabbit IgG	AlexaFluor™ 564	Thermo Fisher Scientific	A-11035	AB_2534093	1:500

and capillaries were clear and even within the whole sample. The staining intensity and morphology did not differ from that seen in the five control samples stored for 6 months before cutting and stained within 2 weeks after cutting.

4 | DISCUSSION

We discovered that in unfixed cryosections stored at -80°C for <6 months, 9 and 18 years, the epitopes for MyHC-isoforms, dystrophin (sarcolemma) were not compromised. Although some cryosections stained less intense, this was independent of the storage duration at -80°C or the age of the donor. As the MyHC-isoforms, sarcolemma and capillary signals are not being analysed according to fluorescence intensities, but rather in terms of the presence or absence of a signal, adjustment in image acquisition can compensate for a weaker staining without compromising the reliability of image analysis. In fact, none of the sections in the present study were unsuitable for image analysis due to a suboptimal staining result.

The importance of air-tight and temperature-stable storage conditions is well known (Bachman, 2013; McConnell, 1983) and might explain some of the variations in staining intensity between samples

as these conditions might have varied somewhat between samples located in different slide boxes. For instance, the cryosections were divided randomly into 12 slide boxes and taken out of the boxes on the day of the staining ($n=34$ staining days), where some boxes have potentially been opened more frequently than others, or it has been taken longer to find a sample inside the box, so that for instance condensation and refreezing might have occurred that at least in theory could have a negative impact on morphology and epitope stability.

5 | CONCLUSIONS

Our results indicate that cryosections from human *m. vastus lateralis* can be stored for as long as 18 years, and presumable even longer, without having any significant detrimental impact on morphology and epitopes, if optimally stored. Any variation in staining intensity is most likely attributable due to condensation with refreezing that may cause the formation of ice crystals and epitope degradation. We therefore recommend paying attention to optimal storage conditions and minimise the frequency and duration of opening slide boxes to collect samples. Moreover, we suggest to not discard any old cryosections without performing a test staining, as they are most

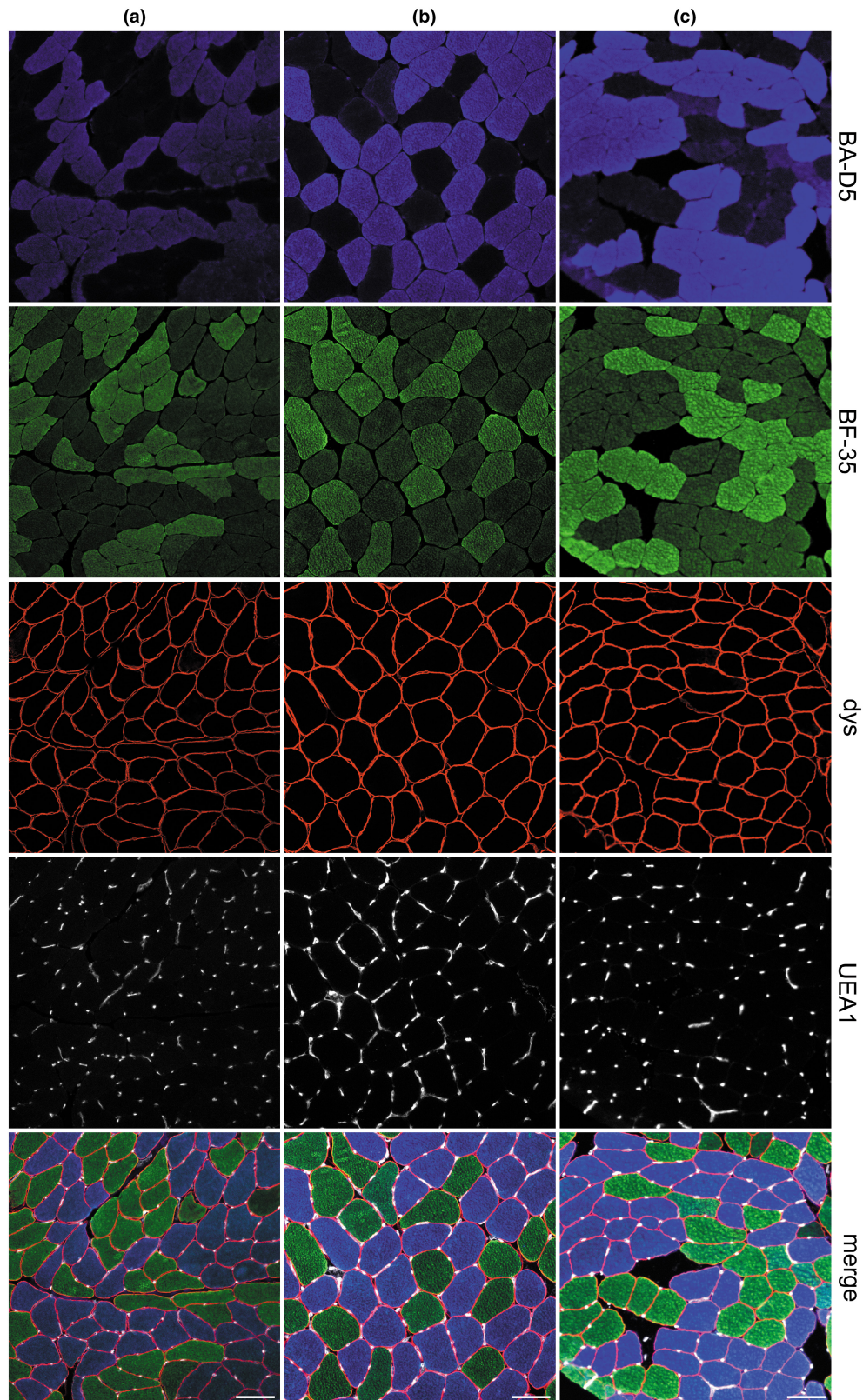


FIGURE 1 Immunofluorescent (IF) labelling of cryosections after different storage durations: Slow muscle fibres are depicted in blue (MyHC-I), fast muscle fibres in green (MyHC-IIa), the sarcolemma in red and capillaries in white. These cryosections of human m. vastus lateralis have been stored for 18 years, 66-year-old man (a), 9 years, 22-year-old man (b) and 2 weeks, 51-year-old woman (c) before IF labelling. Scale bar indicating 100 μm.

likely well preserved and offer an opportunity to use valuable samples for answering additional or new research questions.

AUTHOR CONTRIBUTIONS

Bettina Hutz: Freezing and cryosectioning, immunofluorescence labelling and imaging, interpretation of the results, manuscript preparation, Hans Degens: Cryosectioning and support in manuscript preparation, Marko Korhonen: Recruitment of biopsy donors, study design and supervision, support in manuscript preparation.

ACKNOWLEDGEMENTS

This study was supported in part by grants from the Juho Vainio Foundation, Finnish Ministry of Education and Culture, Yrjö Jahnsson Foundation, Päivikki and Sakari Sohlberg Foundation, and EU Socrates/Erasmus programme.

CONFLICT OF INTEREST STATEMENT

All authors declare that they have no conflicts of interest.

DATA AVAILABILITY STATEMENT

The authors declare that the data of this study are available upon reasonable request.

ORCID

Hans Degens  <https://orcid.org/0000-0001-7399-4841>

Marko T. Korhonen  <https://orcid.org/0000-0003-2550-0784>

REFERENCES

- Bachman, J. (2013) Preparation of slides for microscopy from frozen tissue sections. *Methods in Enzymology*, 533, 217–224.
- Bergström, J. (1962) Muscle electrolytes in man. *Scandinavian Journal of Clinical and Laboratory Investigation*, 14, 511–513.
- Duchenne, G.B.A. (1868) Recherches sur la paralysie musculaire pseudo-hypertrophique, ou paralysie myosclérosique. *Archives Générales de Médecine*, 11, 5–25.

- Edwards, R., Young, A. & Wiles, M. (1980) Needle biopsy of skeletal muscle in the diagnosis of myopathy and the clinical study of muscle function and repair. *New England Journal of Medicine*, 302, 261–271.
- Edwards, R.H.T. (1971) Percutaneous needle-biopsy of skeletal muscle in diagnosis and research. *The Lancet*, 298, 593–595.
- Frontera, W.R., Meredith, C.N., O'Reilly, K.P., Knuttgen, H.G. & Evans, W.J. (1988) Strength conditioning in older men: skeletal muscle hypertrophy and improved function. *Journal of Applied Physiology*, 64, 1038–1044.
- Korhonen, M.T., Cristea, A., Alén, M., Häkkinen, K., Sipilä, S., Mero, A. et al. (2006) Aging, muscle fiber type, and contractile function in sprint-trained athletes. *Journal of Applied Physiology*, 101, 906–917.
- McConnell, J. (1983) Storage and long-term use of human biopsy tissue in histochemical studies. *Journal of Neuroscience Methods*, 8, 385–390.
- Murach, K.A., Dungan, C.M., Kosmac, K., Voigt, B.T., Tourville, T.W., Miller, M.S. et al. (2019) Fiber typing human skeletal muscle with fluorescent immunohistochemistry. *Journal of Applied Physiology*, 127, 1632–1639.
- Nowak, L. & Reyes, P.F. (2008) Muscle biopsy: a diagnostic tool in muscle diseases. *Journal of Histotechnology*, 31, 101–108.
- Sjöström, M. (1975) Ice crystal growth in skeletal muscle fibres. *Journal of Microscopy*, 105, 67–80.
- Song, S., Ahn, C.H. & Kim, G.D. (2020) Muscle fiber typing in bovine and porcine skeletal muscles using immunofluorescence with monoclonal antibodies specific to myosin heavy chain isoforms. *Food Science of Animal Resources*, 40, 132–144.
- Walters, J. & Baborie, A. (2020) Muscle biopsy: what and why and when? *Practical Neurology*, 20, 385–395.

How to cite this article: Hutz, B., Degens, H. & Korhonen, M.T. (2024) Oldies, but goldies—preserved morphology and stability of antigenic determinants in decades-old cryosections of human *m. vastus lateralis*. *Journal of Anatomy*, 00, 1–5. Available from: <https://doi.org/10.1111/joa.14003>