JYX JYVÄSKYLÄN YLIOPISTO UNIVERSITY OF JYVÄSKYLÄ

This is a self-archived version of an original article. This version may differ from the original in pagination and typographic details.

Author(s): Salmivuori, M.; Grönroos, M.; Tani, T.; Pölönen, I.; Räsänen, J.; Annala, L.; Snellman, E.; Neittaanmäki, N.

Title: Hexyl aminolevulinate, 5-aminolevulinic acid nanoemulsion, and methyl aminolevulinate in photodynamic therapy of non-aggressive basal cell carcinomas : A non-sponsored, randomized, prospective and double-blinded trial

Year: 2020

Version: Published version

Copyright: © 2020 Wiley-Blackwell

Rights: In Copyright

Rights url: http://rightsstatements.org/page/InC/1.0/?language=en

Please cite the original version:

Salmivuori, M., Grönroos, M., Tani, T., Pölönen, I., Räsänen, J., Annala, L., Snellman, E., & Neittaanmäki, N. (2020). Hexyl aminolevulinate, 5-aminolevulinic acid nanoemulsion, and methyl aminolevulinate in photodynamic therapy of non-aggressive basal cell carcinomas : A non-sponsored, randomized, prospective and double-blinded trial. Journal of the European Academy of Dermatology and Venereology, 34(12), 2781-2788. https://doi.org/10.1111/jdv.16357

Accepted Article

DR. MARI SALMIVUORI (Orcid ID : 0000-0003-0193-0552)
MR. JANNE RÄSÄNEN (Orcid ID : 0000-0003-3809-384X)
DR. NOORA NEITTAANMÄKI (Orcid ID : 0000-0002-8733-5510)

Article type : Original Article

Hexyl aminolevulinate, 5-aminolevulinic acid nanoemulsion, and methyl aminolevulinate in photodynamic therapy of non-aggressive basal cell carcinomas: A non-sponsored, randomized, prospective and double-blinded trial

M. Salmivuori[1,2,3], M. Grönroos[1,2], T. Tani[1,4], I. Pölönen[5], J. Räsänen[1,2], L. Annala[5], E. Snellman[2,6], N. Neittaanmäki[7]

1) Department of Dermatology and Allergology, Päijät-Häme Social and Health Care Group, Lahti, Finland
2) Department of Dermatology, Tampere University Hospital and Tampere University, Faculty of Medicine and Health Technology, Finland
3) Department of Dermatology and Allergology, Helsinki University Hospital, Finland
4) HUSLAB Laboratory Services, Helsinki University Hospital, Hospital District of Helsinki and Uusimaa, Finland
5) Faculty of Information Technology, University of Jyväskylä, Finland
6) Department of Dermatology, Satasairaala, Pori, Finland
7) Departments of Pathology and Dermatology, Institutes of Biomedicine and Clinical Sciences, Sahlgrenska Academy, University of Gothenburg, Sweden

Key words: non-aggressive basal cell carcinoma, photodynamic therapy, methyl aminolevulinate, 5-aminolevulinic acid nanoemulsion, hexyl aminolevulinate

Short title: PDT of non-aggressive BCCs with MAL, BF-200 ALA and HAL

Word count: Abstract: 248 words; Body text: 2997 words; 1 table; 3 figures

Corresponding author: Mari Salmivuori, Department of Dermatology and Allergology, Keskussairaalankatu 7, 15830 Lahti, Finland

This article has been accepted for publication and undergone full peer review but has not been through the copyediting, typesetting, pagination and proofreading process, which may lead to differences between this version and the Version of Record. Please cite this article as doi: 10.1111/jdv.16357

This article is protected by copyright. All rights reserved

Mobile: +358 505 355 616, e-mail: mari.salmivuori@tuni.fi

Conflict of interest: The authors declare no conflict of interests.

Funding: This clinical trial has been funded by research grants from the Finnish Dermatological Society, the Cancer Foundation Finland, the Foundation for Clinical Chemistry Research, the Instrumentarium Science Foundation, Tampere University, and the Competitive Research Financing of the Expert Responsibility Area of Tampere University Hospital.

Accepted Article

ABSTRACT

Background In the photodynamic therapy (PDT) of non-aggressive basal cell carcinomas (BCCs), 5-aminolevulinic acid nanoemulsion (BF-200ALA) has shown non-inferior efficacy when compared with methyl aminolevulinate (MAL), a widely used photosensitizer. Hexyl aminolevulinate (HAL) is an interesting alternative photosensitizer. To our knowledge, this is the first study using HAL-PDT in the treatment of BCCs.

Objectives To compare the histological clearance, tolerability (pain and post-treatment reaction), and cosmetic outcome of MAL, BF-200 ALA, and low-concentration HAL in the PDT of non-aggressive BCCs.

Methods Ninety-eight histologically verified non-aggressive BCCs met the inclusion criteria, and 54 patients with 95 lesions completed the study. The lesions were randomized to receive LED-

This article is protected by copyright. All rights reserved

PDT in two repeated treatments with MAL, BF-200 ALA, or HAL. Efficacy was assessed both clinically and confirmed histologically at three months by blinded observers. Furthermore, cosmetic outcome, pain, post-treatment reactions fluorescence, and photobleaching were evaluated.

Results According to intention-to-treat analyses, the histologically confirmed lesion clearance was 93.8% (95% confidence interval [CI] = 79.9–98.3) for MAL, 90.9% (95% CI = 76.4–96.9) for BF-200 ALA, and 87.9% (95% CI = 72.7–95.2) for HAL, with no differences between the arms (p=0.84). There were no differences between the arms as regards pain, post-treatment reactions, or cosmetic outcome.

Conclusions PDT with low-concentration HAL and BF-200 ALA have a similar efficacy, tolerability, and cosmetic outcome compared to MAL. HAL is an interesting new option in dermatological PDT, since good efficacy is achieved with a low concentration.

Registration numbers: EudraCT with 2014-002746-50 and clinicaltrial.gov with NCT02367547.

INTRODUCTION

The incidence of basal cell carcinoma (BCC), especially the superficial subtype (sBCC) is rising[1,2]. BCC is as common as all other malignancies combined, and thus causes remarkable health care costs[3,4]. The sBCC and the thin nodular BCC (nBCC) are often classified as low-risk tumours, and they can be treated with non-surgical options[5], i.e. photodynamic therapy (PDT), imiquimod or 5-fluorourasil (5-FU), where imiquimod has superior efficacy [6-7]. The advantages of PDT include a superior cosmetic outcome and short application and down times[8,9].

PDT uses a combination of light, a photosensitizing agent (an exogenous source for photoactive protoporphyrin IX, PpIX), and oxygen to generate a radical oxygen species that cause cell apoptosis and necrosis[10,11]. Of these factors, PpIX production in particular seems to be related to cell death[12]. Thus, changing the prodrug of PpIX could be an effective way to enhance the reaction.

The PpIX produced can be measured as the fluorescence of a photosensitizer[13]. Fluorescence and especially photobleaching (i.e. the difference in fluorescence measured before and after illumination) correlate with the accumulation of PpIX and with efficacy[14,15].

5-aminolevulinic acid (5-ALA) was the first photosensitizer in PDT of skin malignancies with selectivity in the tumour tissue[10]. The esters of 5-ALA like methyl aminolevulinate (MAL) are more lipophilic, and a shorter incubation time is needed, when compared to 5-ALA[11]. With

This article is protected by copyright. All rights reserved

nanoemulsion of 5-ALA (BF-200 ALA) at a 10% concentration a greater fluorescence was detected after incubation time, when compared to 20% 5-ALA[16]. In addition, BF-200 ALA was shown to penetrate deeper in an *ex vivo* skin model, when compared to MAL[17]. The efficacy of BF-200 ALA is shown to be non-inferior compared to MAL in PDT of non-aggressive BCCs[18]. Hexyl aminolevulinate (HAL) is a long-chain lipophilic 5-ALA ester, capable to produce significantly higher fluorescence intensities in the human epidermis and superficial dermis, when compared to MAL – though in the mid and deep dermis the intensity is only slightly higher[19]. An equal fluorescence intensity is achieved in the rat skin using HAL2% and MAL20%[20]. HAL, BF-200 ALA and MAL seem to be equally tolerated when applied on normal human skin[21].

This prospective trial aims to compare the efficacy and tolerability (i.e. pain and post-treatment-reaction) of MAL, BF-200 ALA, and low-concentration HAL in the PDT of non-aggressive BCCs.

Materials and methods

The protocol complied with the Declaration of Helsinki and was approved by the Ethics Committee of Tampere University Hospital and by the Finnish Medicines Agency. Written informed consent was obtained from all participants. Patients were recruited from those referred to the Department of Dermatology and Allergology at Päijät-Häme Social and Health Care Group, Lahti, Finland, between March 2015 and September 2018.

The three parallel arms were MAL16% (Metvix®, Galderma Norcid AB), and BF-200 ALA7.8% (Ameluz®, Biofrontera), and HAL2% (mixture of Hexvix® powder, Photocure ASA, and unguentum M cream, Allmirall Hermal GmbH) with allocation ratio of 1:1:1. Of these, MAL and BF-200 ALA are approved for the PDT of non-aggressive BCCs, and HAL is approved for the photodynamic diagnosis of uroepithelial cancer and the treatment of cervical dysplasia by the European Medicines Agency.

Inclusion and exclusion criteria

Patients over 18 years old presenting with a superficial BCC clinically were enrolled. Exclusion criteria included pregnancy, lactation, allergy/intolerance to the photosensitizers used, porphyria, and photosensitivity.

The target lesions had to be located on the trunk or extremities. Lesions located on the face or head were not eligible. In the case of multiple BCCs in the same patient, we included only

Accepted Article

This article is protected by copyright. All rights reserved

lesions located at least 10 cm apart from each other to minimize mixing up the photosensitizers[22]. The target BCCs were included according to clinical inspection with a dermatoscope, and randomized to one of the three arms at the recruitment visit. However, a diagnostic biopsy was taken from all included lesions prior to treatment. Lesions with some other histopathology than BCC were excluded from the analyses. Only lesions confirmed to be non-aggressive, i.e. a superficial or thin nodular – defined as growing into the epidermal-dermal junction or the most upper third of the dermis – could be included for analyses.

Outcomes

The primary outcome was histologically verified clearance at three months. The secondary outcomes were pain during the illumination with the use of a long-acting local anaesthetic prior to pre-handling, post-treatment reaction, cosmetic outcome, and fluorescence/photobleaching.

Power calculations, randomization and treatment allocation

In the power calculations (alpha=0.05, power=0.85, delta=0.30), it was assumed that BF-200 ALA/HAL would be superior to MAL, as MAL has an efficacy of 72.8% at twelve months[9], although the efficacy might be even lower in a group aged over 60 years[23]. Thus the efficacy of MAL was assumed to be 65%. Same delta-value was used both for BF-200 ALA and HAL. Thus, the needed sample size was 31 lesions/arm. The initial set (93 lesions) was randomized using a web-based validated program, Research randomizer.org®. As the trial proceeded, we noticed of the other histology than BCC being notable, and performed another set of randomization (24 lesions) with closed envelopes (at the moment troubles using Research randomizer®). In total, 117 lesions (39/arm) were randomized, Figure 1.

Protocol

Prior to treatment (performed by M.S. and J.R.), the lesions were assessed with a dermatoscope (Dermlite® DL3 or DL3N, 3GenCA, USA, or Heine Delta 20T®). Treatment areas including the lesion, a 5 mm margin, and a biopsy site were marked on plastic sheets with scaling (1x1mm squares). A diagnostic 3 mm punch biopsy was taken prior to curettage at the first session (PDT I), and local anaesthetics (1:1 mixture of lidocaine 10mg/ml cum epinephrine 10 µg/ml to ropivacaine 7.5mg/ml) were infiltrated prior to any procedures at both sessions. Curettage i.e. removing crusts/scabs and handling the whole treatment area was used for all of the lesions. If needed

Accepted Article

This article is protected by copyright. All rights reserved

aluminium chloride was used for haemostasis, and in PDT I the biopsy site was closed with a transparent stitch (Monocryl 4-0). Thereafter a 1 mm thick layer of photosensitizer (treatment area calculated from plastic sheets in mm^2, photosensitizer scaled with 1 mg/mm^2 dosing) was applied to the treatment area followed by three hours occlusion with a light-impermeable cover before illumination (Aktilite, CL128, Galderma, 37 J/cm^2 per session). All lesions were illuminated with the same total time of 7 min and 24 seconds, but recording of pain and illuminating together took approximately 8 minutes of time. The second session (PDT II) followed 8–14 days after PDT I. Figure 2 represents an example case.

Assessment of efficacy

At the three-month follow-up visit an experienced dermatologist (M.G.), blinded for treatment, evaluated all lesions with inspection and with a dermatoscope, and took 3 mm control punch biopsies near the diagnostic biopsy site using the marked plastic sheets as guidance. Additional 3 mm punch biopsies were taken from clinically suspicious sites if needed. Non-responsive lesions were completely excised as a second line treatment, which allowed us to evaluate if a mixed histology with aggressive features would exist. An experienced pathologist (T.T.), blinded for treatment, assessed all histopathological specimens.

Assessment of the treatment tolerability and cosmetic outcome

Pain was assessed by patients, blinded for photosensitizer, using a visual analogue scale (VAS)[24] at the beginning, in the middle, and in the end of each illumination. No other pain management was used. For our analyses we named the difference of VAS in the middle and at the beginning as 4 min, and the difference of VAS in the end and at the beginning as 8 min. Thus we acknowledged that the pain experienced by the patient at the beginning of the illumination could be something else than zero.

Post-treatment reactions (oedema, erythema, erosion, and crust formation) were photographed 8–14 days after PDT I and assessed afterwards on a five-point scale (none/minimal/mild/moderate/severe) by the blinded observer (M.G.). The cosmetic outcome was assessed on a four-point-scale (excellent/good/fair/poor) at the three-month follow-up visit by the blinded observer (M.G.).

Fluorescence measurement

This article is protected by copyright. All rights reserved

Fluorescence images were taken at the beginning and end of illumination using a digital camera (Canon Ixus 130, 14.1 megapixel with the set-up ISO800, FW 2.8, no zoom), a Wood's light (Philips Burton®, Somerset, USA, kept hand-held at a distance of about 8 cm) and a yellow filter lens (Hoya HMC, yellow-green xo, attached to the top of the Wood's light), as used by Neittaanmäki-Perttu et al.[21] The photosensitizer was removed with saline solution before imaging.

Statistical analyses and calculations of fluorescence

Statistical analyses were conducted with a professional statistician using SPSS 23.0 (IBM SPSS Statistics for Windows, Version 23.0. Armonk, NY: IBM Corp.), or a mathematician (I.P.) with Python 3.6 using Numpy and Scipy libraries.

As statistical methods, Fisher's exact test was used to compare the efficacy, post-treatment reactions, and the cosmetic outcome. As regards pain, the comparison between the arms was performed with the Kruskall–Wallis test, and the comparison between the sessions in each arm with the Wilcoxon Signed Rank Test. For fluorescence and photobleaching, the ANOVA test was used to compare the treatment arms, and to calculate the correlation between the histological clearance and the fluorescence/photobleaching, the Chi-squared was used.

Fluorescence images were processed semi-automatically using affine transformation and manually selected matching points by a mathematician (L.A.) with Python 3.6. The intensity was extracted in the red light channel to achieve arbitrary units (A.U.) for fluorescence and photobleaching (as the absolute difference of the mean fluorescence before and after illuminating).

Results

Altogether 98 histologically verified non-aggressive BCC (in 57 patients) were included to the study, but there were three dropouts. Thus 54 patients completed the study with 95 non-aggressive BCCs (Figure 1). Table 1 represents the patients and lesion characteristics. In total, six residual lesions were found at three months follow-up (1/31 in MAL, 3/33 in BF-200 ALA, and 2/31 in HAL). In the final excision of non-responsive lesions, there were no aggressive subtypes.

Lesion clearance with intention-to-treat analyses

Among the 98 non-aggressive BCCs, i.e. including the dropouts, the histologically verified efficacy was 93.8% (95% CI = 79.9–98.3) for MAL, 90.9% (95% CI = 76.4–96.9) for BF-200

Accepted Article

This article is protected by copyright. All rights reserved

ALA, and 87.9% (95% CI = 72.7–95.2) for HAL (in the comparison of the arms; p=0.84). Thus, there were no differences between the arms in terms of efficacy.

Tolerability and cosmetic outcome

Pain results for the 95 BCCs of the 54 patients who completed the study are reported in Figure 3A. No differences were found in pain between the arms during illumination (MAL vs BF-200 ALA vs HAL; PDT I 4 min p=0.21, 8 min p=0.18; PDT II 4 min p=0.47, 8 min p=0.87). In the HAL group, the second session was more painful than the first session (PDT I vs PDT II; 4 min p=0.006, 8 min p=0.005). There was no difference in pain between the sessions in the other arms (PDT I vs PDT II; MAL 4 min p=0.17, 8 min p=0.79; BF-200 ALA 4 min p=0.45, 8 min p=0.43).

Among the 95 BCCs, no differences were either found in the post-treatment reactions (p=0.49; Figure 3B, and Figure 2E). There was one treatment-related withdrawal from the trial, as one patient from the MAL group experienced remarkable swelling, oedema, erythema, and haematoma in the treatment area after PDT I, and refused to attend PDT II.

Among the 95 BCCs, the cosmetic outcome was regarded as good/excellent in 77.4% of the lesions in the MAL group, 75.7% in the BF-200 ALA group, and 61.3% in the HAL group, with no differences between the arms (p=0.61; Figure 3C, and Figure 2F).

Fluorescence and photobleaching

In total, fluorescence images were available from 84 lesions in 49 patients from PDT I, and respectively from 91 lesions in 51 patients from PDT II. At the beginning of the illumination, fluorescence was lower in HAL2% compared to MAL16% and BF-200 ALA7.8% (PDT I p=0.043 and PDT II p=0.043). However, there was no statistical significant difference in photobleaching between the arms (PDT I p=0.09 and PDT II p=0.42). We found no correlation between the histological clearance and the photobleaching (PDT I p=0.40, PDT II p=0.77) or fluorescence (PDT I p=0.77, PDT II p=0.55). Fluorescence and photobleaching showed a wide variation.

Discussion

To our knowledge, this is the first trial using HAL-PDT for non-aggressive BCCs. Morrow et al. have earlier suggested that HAL is more effective in equimolar doses compared to MAL and 5-ALA[25]. Dögnitz et al. reported that HAL could be used in smaller concentrations to achieve a similar distribution of PpIX in the BCC tissue compared to 5-ALA[26]. Our results support the idea.

This article is protected by copyright. All rights reserved

Kiesslich et al. demonstrated for 5-ALA, MAL, and HAL *in vitro* that after a certain threshold limit, the intracellular PpIX concentration doesn't rise by increasing the concentration of the prodrug, but under this threshold the concentration matters, also the incubation time of the prodrug[27]. There are many variables in PDT, and thus the protocol used can affect the efficacy[28,29]. Consequently, the optimal concentration and protocol for HAL-PDT of non-aggressive BCCs is still unexplored.

In a recent multi-centre trial, Morton et al. reported a three-month clinical clearance of 91.8% for MAL and 93.4% for BF-200 ALA in the PDT of non-aggressive BCCs[18]. In another multi-centre trial, Arits et al. reported clinical clearance of 84.2% at three months for MAL-PDT[9]. We and Morton et al. used curettage, but Arits et al. reported 'a non-traumatic surface preparation'. In our experience, some small trauma can occur in curettage, and physical pre-treatment in PDT enhances the PpIX uptake[30,31].

Morton et al. have shown the similar tolerability of BF-200 ALA and MAL[18]. Interestingly, HAL seems to have a more precise effect on the site of application compared to 5-ALA on mice skin, and this could be beneficial in terms of post-treatment reactions[32]. Neittaanmäki-Perttu et al. reported that on healthy human skin, HAL2% caused a similar erythema as BF-200 ALA7.8% and MAL16%, and in terms of pain, there was a significant difference in the respective comparison[21]. In our results, for BCC we did not found any differences between the arms in terms of adverse events.

As regarding pain, Lindeburg et al. have reported that PDT II is more painful than PDT I when treating actinic keratosis and sBCC with MAL-PDT[33]. Perhaps due to the small sample size, this difference was found only for HAL in our results. Our mean and median VAS score was 2.3 at its highest. Interestingly, Morton et al. had a highest mean pain score (on a 1–10 scale) of 4.5 without analgesia, despite the use of a BF-RhodoLED (Biofrontera) light source with reduced pain levels compared to Aklite (Galderma)[34]. Thus, it seems that a long-acting local anaesthetics prior to pre-handling could be effective in pain management – though this differs from the European PDT guidelines[35]. Previously, nerve blocking has been shown to be an effective option, whereas topical analgesia has not[36]. Our method should be studied more closely in a prospective and randomized setting, including in carcinomas in situ and head locations, where pain can be a major obstacle[37].

In PDT, the use of local analgesia can have a potential impact on efficacy through vasoconstriction, pH, and oxygen availability [37]. The use of epinephrine in particular could lead to

Accepted Article

This article is protected by copyright. All rights reserved

this. Infiltration of local anaesthetics has earlier been used during illumination with lidocaine/prilocaine cum ropivacaine, and also cum epinephrine, with good treatment success[38,39]. However, our pain management protocol didn't affect the results.

We found a good/excellent cosmetic outcome in 71.6% of all the lesions at three months. We did not achieve the results of Jansen et al.[8] (the same trial as by Arits et al.), who reported a good/excellent cosmetic outcome in MAL-PDT for 89.5% of patients at five years. However, the cosmetic outcome tends to improve over time[18].

Non-surgical options provide a cost-effective alternative to surgery in the treatment of non-aggressive BCCs[40], and patients with multiple lesions or facial lesions are willing to risk the recurrence rate for a better cosmetic outcome[41]. The advantages of PDT include the cosmetic outcome[8], the shorter application and down times, and the mode of delivery[9], but the major disadvantage is the lower efficacy compared to imiquimod[6]. However, the topical creams demand good patient compliance and correct patient selections, as the creams are applied by the patient at home for a number of weeks. Regarding the economic aspect of low-concentration HAL, there could be benefits in the manufacture of the cream, as only a low concentration is demanded. Interestingly in the daylight PDT of thin actinic keratosis, a similar efficacy was achieved with HAL0.2% as compared to MAL16%[42].

The strengths of our study are the investigator-initiated double-blinded design, histopathological confirmation in addition to the clinical evaluation, and the complete excision of the non-responsive lesions to examine the possible underlying mixed histologies as the cause for treatment failure. We assumed our patients would be over 60 years, and this corresponded to our material quite accurately; only 6/54 of the analysed patients were under 60 years.

The limitations of our study design are a limited sample size and optimistic assumptions in the power calculations. The taking of diagnostic biopsies at the first treatment session should also be considered a limitation, since these could potentially lead to lesion resolution due to inflammation induced by the biopsy. A limitation of the pain analyses was the absence of a control group for local anaesthetics. Furthermore, the summation of pain may have occurred in patients with multiple lesions, but in our protocol lesions (not patients) were randomized, and thus the possible effect should be quite equal for all arms. A major limitation in the fluorescence/photobleaching analyses was the lack of a validated imaging system.

This article is protected by copyright. All rights reserved

Accepted Article

In conclusion, HAL is an interesting new option for dermatological PDT. The efficacy and tolerability of low-concentration HAL was comparable with BF-200 ALA and MAL. Dose-finding studies and larger trials are warranted in the future for HAL.

Acknowledgments

We want to thank Marc Bauman and Teija Inkinen at Biomedicum, Helsinki University, for the HAL analyses, Maarit Bäckman from the YA pharmacy for manufacturing the HAL cream, Mika Helminen from Tampere University Hospital for the statistical analyses, Ulla Tuovinen and the staff of Päijät-Häme Dermatology clinic for recruiting the patients, and our assisting nurse Ulla Oesch-Lääveri for everything.

References

1 Lomas A, Leonardi-Bee J, Bath-Hextall F. A systematic review of worldwide incidence of nonmelanoma skin cancer. *Br J Dermatol* 2012; **166**:1069-80.

2 Arits, A H M M., Schlangen MHJ, Nelemans PJ, Kelleners-Smeets NWJ. Trends in the incidence of basal cell carcinoma by histopathological subtype. *Journal of the European Academy of Dermatology & Venereology* 2011; **25**:565-9.

3 Holm A, Nissen CV, Wulf HC. Basal Cell Carcinoma is as Common as the Sum of all Other Cancers: Implications for Treatment Capacity. *Acta Derm Venereol* 2016; **96**:505-9.

4 Bentzen J, Kjellberg J, Thorgaard C, et al. Costs of illness for melanoma and nonmelanoma skin cancer in Denmark. *European Journal of Cancer Prevention* 2013; **22**:569-76.

5 Trakatelli M, Morton C, Nagore E, et al. Update of the European guidelines for basal cell carcinoma management. *European Journal of Dermatology* 2014; **24**:312-29.

6 Jansen MHE, Mosterd K, Arits, Aimee H M M, et al. Five-Year Results of a Randomized Controlled Trial Comparing Effectiveness of Photodynamic Therapy, Topical Imiquimod, and Topical 5-Fluorouracil in Patients with Superficial Basal Cell Carcinoma. *J Invest Dermatol* 2018; **138**:527-33.

Accepted Article

This article is protected by copyright. All rights reserved

7 Roozeboom MH, Arits, Aimee H M M., Mosterd K, et al. Three-Year Follow-Up Results of Photodynamic Therapy vs. Imiquimod vs. Fluorouracil for Treatment of Superficial Basal Cell Carcinoma: A Single-Blind, Noninferiority, Randomized Controlled Trial. *J Invest Dermatol* 2016; **136**:1568-74.

8 Jansen MHE, Koekelkoren FHJ, Nelemans PJ, et al. Comparison of long-term cosmetic outcomes for different treatments of superficial basal cell carcinoma. *J Am Acad Dermatol* 2018; **79**:961-4.

9 Arits, Aimee H M M, Mosterd K, Essers BA, et al. Photodynamic therapy versus topical imiquimod versus topical fluorouracil for treatment of superficial basal-cell carcinoma: a single blind, non-inferiority, randomised controlled trial. *Lancet Oncology* 2013; **14**:647-54.

10 Kennedy JC, Pottier RH, Pross DC. Photodynamic therapy with endogenous protoporphyrin IX: basic principles and present clinical experience. *Journal of Photochemistry & Photobiology.B - Biology* 1990; **6**:143-8.

11 Ozog DM, Rkein AM, Fabi SG, et al. Photodynamic Therapy: A Clinical Consensus Guide. *Dermatologic Surgery* 2016; **42**:804-27.

12 Lee JB, Choi JY, Chun JS, et al. Relationship of protoporphyrin IX synthesis to photodynamic effects by 5-aminolaevulinic acid and its esters on various cell lines derived from the skin. *Br J Dermatol* 2008; **159**:61-7.

13 Tyrrell J, Campbell S, Curnow A. Validation of a non-invasive fluorescence imaging system to monitor dermatological PDT. *Photodiagnosis & Photodynamic Therapy* 2010; **7**:86-97.

14 Tyrrell JS, Campbell SM, Curnow A. The relationship between protoporphyrin IX photobleaching during real-time dermatological methyl-aminolevulinate photodynamic therapy (MAL-PDT) and subsequent clinical outcome. *Lasers in Surgery & Medicine* 2010; **42**:613-9.

15 Tyrrell J, Paterson C, Curnow A. Regression Analysis of Protoporphyrin IX Measurements Obtained During Dermatological Photodynamic Therapy. *Cancers* 2019; **11**.

Accepted Article

This article is protected by copyright. All rights reserved

16 Schmitz L, Novak B, Hoeh A, et al. Epidermal penetration and protoporphyrin IX formation of two different 5-aminolevulinic acid formulations in ex vivo human skin. *Photodiagnosis & Photodynamic Therapy* 2016; **14**:40-6.

17 Maisch T, Santarelli F, Schreml S, et al. Fluorescence induction of protoporphyrin IX by a new 5-aminolevulinic acid nanoemulsion used for photodynamic therapy in a full-thickness ex vivo skin model. *Exp Dermatol* 2010; **19**:302.

18 Morton CA, Dominicus R, Radny P, et al. A randomized, multi-national, non-inferiority, phase III trial to evaluate the safety and efficacy of BF-200 ALA gel versus MAL cream in the treatment of non-aggressive basal cell carcinoma with photodynamic therapy (PDT).. *Br J Dermatol* 2018; **179**;309–319.

19 Togsverd-Bo K, Idorn LW, Philipsen PA, et al. Protoporphyrin IX formation and photobleaching in different layers of normal human skin: methyl- and hexylaminolevulinate and different light sources. *Exp Dermatol* 2012; **21**:745-50.

20 Togsverd-Bo K, Lerche CM, Philipsen PA, et al. Porphyrin biodistribution in UV-exposed murine skin after methyl- and hexyl-aminolevulinate incubation. *Exp Dermatol* 2012; **21**:260-4.

21 Neittaanmaki-Perttu N, Neittaanmaki E, Polonen I, et al. Safety of Novel Amino-5-laevulinate Photosensitizer Precursors in Photodynamic Therapy for Healthy Human Skin. *Acta Derm Venereol* 2016; **96**:108-10.

22 Palsson S, Gustafsson L, Bendsoe N, et al. Kinetics of the superficial perfusion and temperature in connection with photodynamic therapy of basal cell carcinomas using esterified and non-esterified 5-aminolaevulinic acid. *Br J Dermatol* 2003; **148**:1179-88.

23 Lindberg-Larsen R, Solvsten H, Kragballe K. Evaluation of recurrence after photodynamic therapy with topical methylaminolaevulinate for 157 basal cell carcinomas in 90 patients. *Acta Derm Venereol* 2012; **92**:144-7.

24 Hawker GA, Mian S, Kendzerska T, French M. Measures of adult pain: Visual Analog Scale for Pain (VAS Pain), Numeric Rating Scale for Pain (NRS Pain), McGill Pain Questionnaire

Accepted Article

This article is protected by copyright. All rights reserved

(MPQ), Short-Form McGill Pain Questionnaire (SF-MPQ), Chronic Pain Grade Scale (CPGS), Short Form-36 Bodily Pain Scale (SF-36 BPS), and Measure of Intermittent and Constant Osteoarthritis Pain (ICOAP). *Arthritis care & research* 2011; **63**:240.

25 Morrow DIJ, McCarron PA, Woolfson AD, et al. Hexyl aminolaevulinate is a more effective topical photosensitiser precursor than methyl aminolaevulinate and 5-aminolaevulinic acids when applied in equimolar doses. *J Pharm Sci* 2010; **99**:3486-98.

26 Dognitz N, Salomon D, Zellweger M, et al. Comparison of ALA- and ALA hexyl-ester-induced PpIX depth distribution in human skin carcinoma. *Journal of Photochemistry & Photobiology.B - Biology* 2008; **93**:140-8.

27 Kiesslich T, Helander L, Illig R, et al. Real-time analysis of endogenous protoporphyrin IX fluorescence from delta-aminolevulinic acid and its derivatives reveals distinct time- and dose-dependent characteristics in vitro. *J Biomed Opt* 2014; **19**:085007.

28 Wang H, Xu Y, Shi J, et al. Photodynamic therapy in the treatment of basal cell carcinoma: a systematic review and meta-analysis. *Photodermatol Photoimmunol Photomed* 2015; **31**:44-53.

29 Roozeboom MH, Arits, A H H M., Nelemans PJ, Kelleners-Smeets NWJ. Overall treatment success after treatment of primary superficial basal cell carcinoma: a systematic review and meta-analysis of randomized and nonrandomized trials. *Br J Dermatol* 2012; **167**:733-56.

30 Bay C, Lerche CM, Ferrick B, et al. Comparison of Physical Pretreatment Regimens to Enhance Protoporphyrin IX Uptake in Photodynamic Therapy: A Randomized Clinical Trial. *JAMA Dermatology* 2017; **153**:270-8.

31 Nissen CV, Wiegell SR, Philipsen PA, Wulf HC. Short-term chemical pretreatment cannot replace curettage in photodynamic therapy. *Photodermatol Photoimmunol Photomed* 2016; **32**:146-52.

32 Casas A, Perotti C, Fukuda H, et al. ALA and ALA hexyl ester-induced porphyrin synthesis in chemically induced skin tumours: the role of different vehicles on improving photosensitization. *Br J Cancer* 2001; **85**:1794-800.

Accepted Article

This article is protected by copyright. All rights reserved

33 Lindeburg KEK, Brogaard HMV, Jemec GBE. Pain and photodynamic therapy. *Dermatology* 2007; **215**:206-8.

34 Zaar O, Sjoholm Hylen A, Gillstedt M, Paoli J. A prospective, randomized, within-subject study of ALA-PDT for actinic keratoses using different irradiation regimes. *Photodermatol Photoimmunol Photomed* 2018; **34**:338-42.

35 Morton CA, Szeimies R, Sidoroff A, Braathen LR. European guidelines for topical photodynamic therapy part 1: treatment delivery and current indications - actinic keratoses, Bowen's disease, basal cell carcinoma. *Journal of the European Academy of Dermatology & Venereology* 2013; **27**:536-44.

36 Ang JM, Riaz IB, Kamal MU, et al. Photodynamic therapy and pain: A systematic review. *Photodiagnosis & Photodynamic Therapy* 2017; **19**:308-44.

37 Wang B, Shi L, Zhang YF, et al. Gain with no pain? Pain management in dermatological photodynamic therapy. *Br J Dermatol* 2017; **177**:656-65.

38 Borelli C, Herzinger T, Merk K, et al. Effect of subcutaneous infiltration anesthesia on pain in photodynamic therapy: a controlled open pilot trial. *Dermatologic Surgery* 2007; **33**:314-8.

39 Debu A, Sleth J, Girard C, et al. The use of subcutaneous infusion tumescent anesthesia in photodynamic therapy pain control. *Paediatr Anaesth* 2012; **22**:600-1.

40 Aguilar M, de Troya M, Martin L, et al. A cost analysis of photodynamic therapy with methyl aminolevulinate and imiquimod compared with conventional surgery for the treatment of superficial basal cell carcinoma and Bowen's disease of the lower extremities. *Journal of the European Academy of Dermatology & Venereology* 2010; **24**:1431-6.

41 Martin I, Schaarschmidt M, Glocker A, et al. Patient Preferences for Treatment of Basal Cell Carcinoma: Importance of Cure and Cosmetic Outcome. *Acta Derm Venereol* 2016; **96**:355-60.

42 Neittaanmaki-Perttu N, Karppinen TT, Tani T, et al. Long-term Outcome of Low-concentration Hexyl-5-aminolaevulinate Daylight Photodynamic Therapy for Treatment of Actinic Keratoses. *Acta Derm Venereol* 2017; **97**:120-1.

Accepted Article

This article is protected by copyright. All rights reserved

Accepted Article

Figure legends

Figure 1. Flow-chart of the trial.

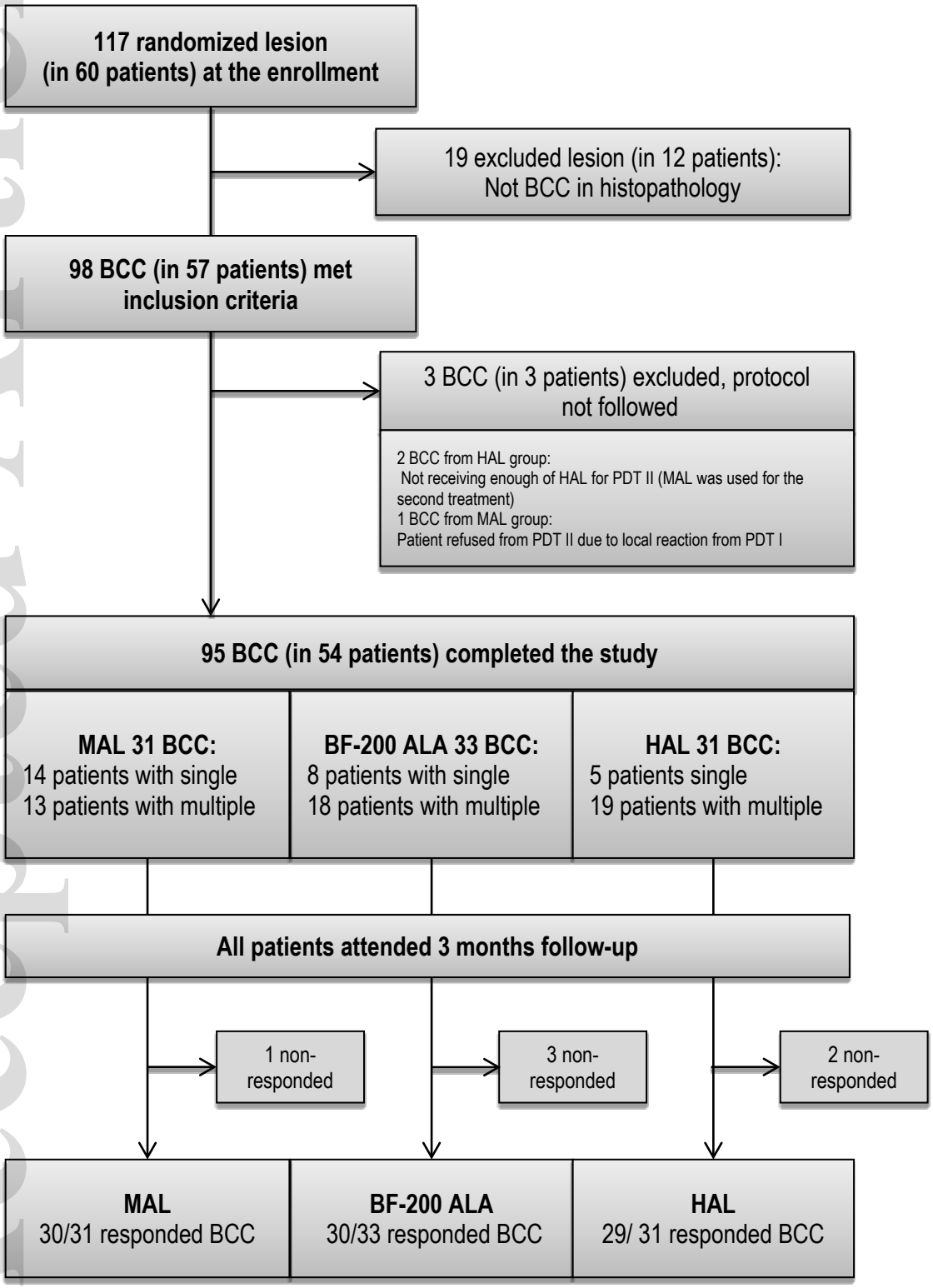

This article is protected by copyright. All rights reserved

Figure 2. Example lesion with images from all phases of the protocol. The example lesion was randomized to the HAL group: A) Clinical image of an sBCC; B) Dermatoscopic image at baseline; C) Marking the lesion, treatment area, and diagnostic biopsy site (copied on plastic sheets with scaling); D) Histology presenting an sBCC in the diagnostic biopsy; E) Post-treatment reaction after PDT I, assessed as strong; F) Clinical image at thee months' follow-up; cosmetic outcome assessed as fair; G) Dermatoscopic image at three months; H) Biopsy site of the control biopsy at three months; and I) Histology of the responsive lesion with reactive changes at three months.

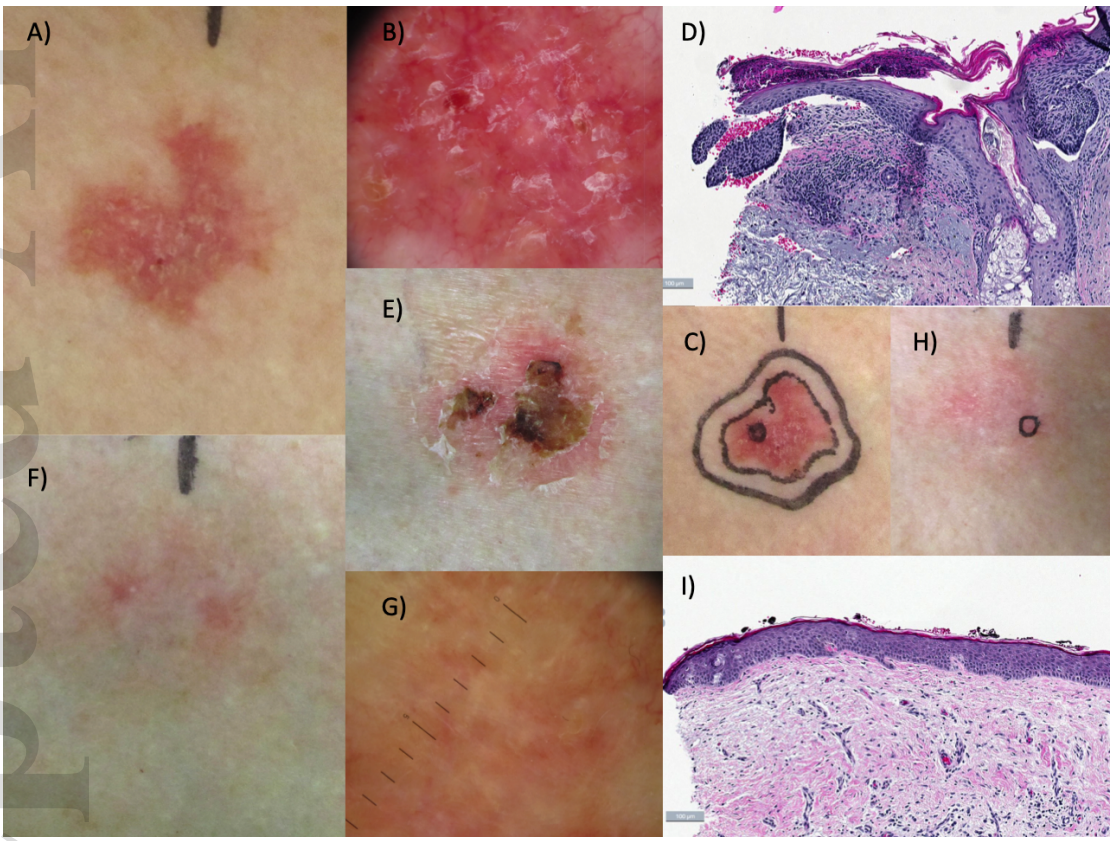

Figure 3. A) Results for pain during the illumination of the PDT for different photosensitizers. In the analyses we named the difference of the recorded VAS in the middle and at the beginning as 4 min (4 min= VAS of the middle – VAS at the beginning), and the difference of recorded VAS in the end and at the beginning was named as 8 min (8 min= VAS of the end – VAS at the beginning); B) severity of post-treatment reactions (visually assessed on scale

Accepted Article

This article is protected by copyright. All rights reserved

none/minimal/mild/moderate/severe); and C) cosmetic outcomes (visually assessed on scale excellent/good/fair/poor).

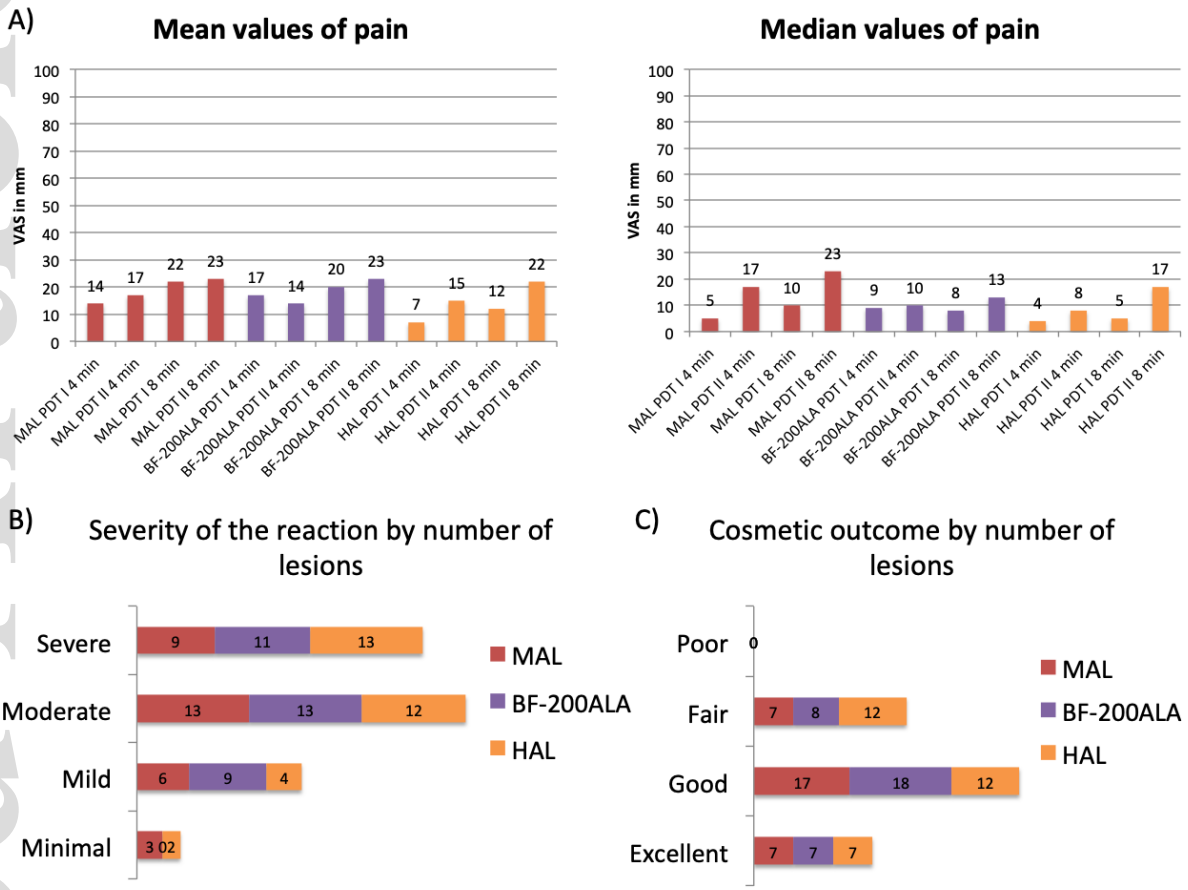

Accepted Article

This article is protected by copyright. All rights reserved

Tables

Table 1. Patient and lesion characteristics.

	MAL	BF-200 ALA	HAL
Patient Characteristics			
Patients	27	26	24
with single lesion	14	8	5
with multiple lesions	13	18	19
Female	10	5	12
Male	17	21	12
Average age in years (range)	71 (47–91)	74 (51–91)	74 (57–91)
Anamnestic skin phototype			
Phototype I	6	4	7
Phototype II	10	13	8
Phototype III	11	9	9
Phototype IV	0	0	0
Immunosuppression or previous radiotherapy	2	1	2
Previous history of skin cancer (AK, MB, MM, SCC, BCC)	19	20	19
Previous history of BCC	13	19	16
Lesion characteristics			
Lesions	31	33	31
Location on trunk	25	26	25
Location on extremities	6	7	6
Average treatment area in mm^2 (range)	439 (150–1100)	377 (130–850)	376 (160–750)
New	30	30	29
Recurrent	1	3	2

Accepted Article

This article is protected by copyright. All rights reserved