Jyväskylän yliopiston julkaisuarkisto
Jyväskylä University Digital Archive

UNIVERSITY OF JYVÄSKYLÄ

This is an electronic reprint of the original article.
This reprint *may differ* from the original in pagination and typographic detail.

Author(s): Neittaanmäki-Perttu, Noora; Grönroos, Mari; Jeskanen, Leila; Pölönen, Ilkka; Ranki, Annamari; Saksela, Olli; Snellman, Erna

Title: Delineating Margins of Lentigo Maligna Using a Hyperspectral Imaging System

Year: 2015

Version:

Please cite the original version:

Neittaanmäki-Perttu, N., Grönroos, M., Jeskanen, L., Pölönen, I., Ranki, A., Saksela, O., & Snellman, E. (2015). Delineating Margins of Lentigo Maligna Using a Hyperspectral Imaging System. Acta Dermato-Venereologica, 95(5), 549-552. https://doi.org/10.2340/00015555-2010

All material supplied via JYX is protected by copyright and other intellectual property rights, and duplication or sale of all or part of any of the repository collections is not permitted, except that material may be duplicated by you for your research use or educational purposes in electronic or print form. You must obtain permission for any other use. Electronic or print copies may not be offered, whether for sale or otherwise to anyone who is not an authorised user.

Acta Derm Venereol 2015; 95: 549–552

INVESTIGATIVE REPORT

Delineating Margins of Lentigo Maligna Using a Hyperspectral Imaging System

Noora NEITTAANMÄKI-PERTTU[1,2], Mari GRÖNROOS[2], Leila JESKANEN[1], Ilkka PÖLÖNEN[3], Annamari RANKI[1], Olli SAKSELA[1] and Erna SNELLMAN[2,4]

Department of Dermatology and Allergology, [1]Helsinki University Central Hospital, Helsinki and [2]Päijät-Häme Central Hospital, Lahti, [3]Department of Mathematical Information Technology, University of Jyväskylä, Jyväskylä, and [4]Department of Dermatology, Tampere University and Tampere University Hospital, Tampere, Finland

Lentigo maligna (LM) is an *in situ* form of melanoma which can progress into invasive lentigo maligna melanoma (LMM). Variations in the pigmentation and thus visibility of the tumour make assessment of lesion borders challenging. We tested hyperspectral imaging system (HIS) in *in vivo* preoperative delineation of LM and LMM margins. We compared lesion margins delineated by HIS with those estimated clinically, and confirmed histologically. A total of 14 LMs and 5 LMMs in 19 patients were included. HIS analysis matched the histopathological analysis in 18/19 (94.7%) cases while in 1/19 (5.3%) cases HIS showed lesion extension not confirmed by histopathology (false positives). Compared to clinical examination, HIS defined lesion borders more accurately in 10/19 (52.6%) of cases (wider, *n* = 7 or smaller, *n* = 3) while in 8/19 (42.1%) cases lesion borders were the same as delineated clinically as confirmed histologically. Thus, HIS is useful for the detection of subclinical LM/LMM borders. *Key words: lentigo maligna; lentigo maligna melanoma; tumour margin assessment; hyperspectral imaging.*

Accepted Nov 12, 2014; Epub ahead of print Nov 14, 2014

Acta Derm Venereol 2015; 95: 549–552.

Noora Neittaanmäki-Perttu, MD, Department of Dermatology and Allergology, Helsinki University Central Hospital, Box 160 Meilahdentie 2, FIN-00029 Helsinki, Finland. E-mail: noora.neittaanmaki@fimnet.fi

Lentigo maligna (LM) is an *in situ* form of melanoma where the neoplastic cells are confined to the epidermis and lack dermal invasion. LM is the most prevalent *in situ* subtype (79–83%) of melanoma. If untreated LM may progress into invasive lentigo maligna melanoma (LMM). The incidence of LM and LMM is constantly increasing over the other melanoma subtypes (1, 2). Early and efficient surgical removal is the method of choice in the treatment of LM and LMM.

Assessment of the borders of LM and LMM is challenging both clinically and histologically. Lesions can extend several cm beyond the clinically estimated margins (3). In clinical practice Wood's light (320–400 nm) is widely used to help the delineation of the tumour margins. Melanin absorbs most of the UV radiation skin is exposed to. Thus, Wood's light increases the contrast between healthy skin and areas presenting even minor increases in epidermal melanin pigmentation (4). However, the pigment content may not be increased in all areas of LM growth.

We have earlier shown that a novel hyperspectral imaging system (HIS) efficiently detects areas of subclinical skin field cancerisation (5). Hyperspectral imaging combines traditional spectroscopy and imaging techniques by producing 3 dimensional data cubes, referred as hyperspectral images, where in addition to spatial (x, y location) information, image contains a spectral graph (z intensity) for each pixel (6). Thus, hyperspectral image consists of a stack of images, of which each image is taken at different narrow wavelength and each pixel in the image has its own spectral signature (Fig 1).

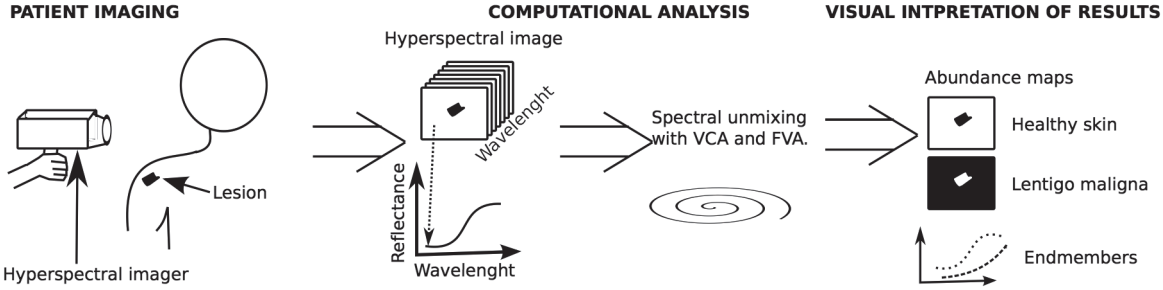

Fig. 1. Hyperspectral imaging process and data analysis. Hyperspectral image (cube) consists of overlapping images, of which each is taken at different wavelength. Each pixel in the hyperspectral image has its own spectral signature. Mathematical algorithms (VCA, FVA) are used to separate the spectra (endmembers) of benign and malignant tissue. The abundance images represent the areas of lesional and healthy skin.

© 2015 The Authors. doi: 10.2340/00015555-2010
Journal Compilation © 2015 Acta Dermato-Venereologica. ISSN 0001-5555

Different biological tissues can be identified from their unique spectral signatures reflecting their biochemical characteristics (6–8). This pilot study aimed to test the feasibility of the HIS in delineation of the margins of LM and LMM preoperatively in order to avoid the need for re-excisions.

MATERIALS AND METHODS

Patients

The study protocol followed the Declaration of Helsinki and was approved by the local ethics committee. All volunteering patients provided their written informed consent. The patients were recruited from those remitted to the Department of Dermatology for their suspected LMs.

Nineteen patients, 7 women and 12 men, with clinically suspect LM or LMM located on their faces or scalps were included in the study. The patients' mean age was 77.9 (range 67–97 years). Three patients displayed skin photo-type I, 8 photo-type II, and 8 photo-type III (9). Nine patients out of 19 had earlier been treated for a non-melanoma skin cancer or premalignant skin lesions (basal cell carcinoma $n=2$, actinic keratosis $n=2$ or both $n=5$). None of the patients had earlier been treated for melanoma.

Clinical assessment of the lesion borders using digital imaging and Wood's light examination

Prior to the imaging processes lesions were evaluated using dermatoscopy (Dermlite® DL3). Clinical assessment of the lesion borders was carried out using Wood's light examination (Burton®) and digital photography (Canon Ixus 130, 14.1 megapixel).

Hyperspectral imaging system and image analysis

All 19 lesions were imaged prior to surgical removal using HIS. The used handheld HIS was developed for the study at the VTT Technical Research Centre of Finland and University of Jyväskylä, Finland. This prototype imaging system consisted of a hyperspectral imager (500–850 nm) (10, 11), external light source of visible and infrared light, fibre optic ring light and a holder for the imager and the ring light. The field of view was 12 cm^2. HIS acquired the diffuse reflectance of the detected skin areas rapidly in a few seconds. The acquired hyperspectral data cube was analysed using an assumption of the linear mixture model (vertex component analysis, VCA and filter vector algorithm FVA) (12–14) to achieve pure spectra (endmembers) of LM/LMM and healthy skin (Fig. S1[1]) and to produce abundance maps for delineation of the lesion borders (Fig. 2, Fig. S2[1]). The hyperspectral imager and the analysing process are shown in Fig. 1, and detailed in Appendix S1[1].

Histopathological sampling

The lesions of 5/19 patients were biopsied before recruiting to the study and excised immediately after the imaging processes. The edges of the specimens were marked with orienting sutures, and inked for orientation. To help mapping the findings for 14/19 patients, we took targeted 3 mm punch biopsies (2–4 per patient) from the middle and from lesions borders, defined using the HIS, and afterwards the lesions were completely excised with wide excision margins. The biopsy sites and excision margins were marked and photographed. An experienced dermatopathologist (LJ) examined the samples without any background information.

RESULTS

The comparative analyses included a total of 14 LMs and 5 LMMs located on the face and scalp (nose $n=1$, ear $n=4$, eyelid $n=2$, forehead $n=2$ and on the cheek area $n=10$) of 19 patients. The invasion depth (Breslow thickness) of the LMMs varied between 0.5 and 1.25 mm. The mean lesion area was 2.4 cm^2 (range 1.6–7.6 cm^2).

In the delineation of LM or LMM margins, HIS analysis matched the histopathological analysis in 18/19 (94.7%)

[1]http://www.medicaljournals.se/acta/content/?doi=10.2340/00015555-2010

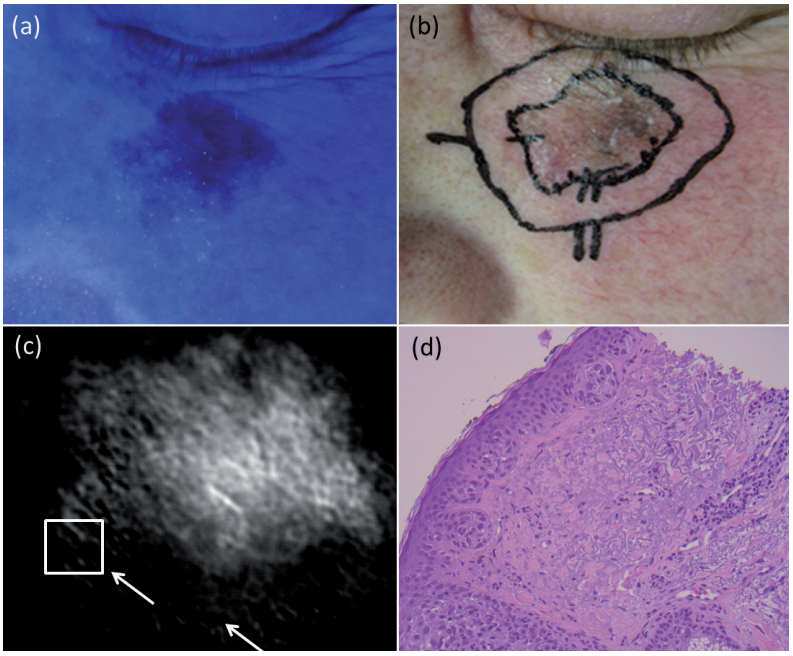

Fig. 2. Lentigo maligna melanoma on lower eyelid (patient 19). (a) Lesion in Wood's light, (b) Clinical wide excision margins, (c) Hyperspectral abundance map showing subclinical lesion extension (arrows), (d) Histological image (HE-staining magnification × 20) of the squared are from Fig 2 c. Atypical melanocytic nests in dermo-epidermal junction and solar elastosis. The wide excision verified the HIS results of subclinical lesion extension.

cases while in 1/19 (5.3%) cases HIS showed lesion extension not confirmed by histopathology (false positives). In 10/19 (52.6%) of the cases lesion margins were delineated more accurately (wider, $n=7$ or smaller, $n=3$) by HIS than by clinical examination with Wood's light, as confirmed by histopathological analysis (Fig 2, Fig S2[1]). In 8/19 (42.1%) cases the lesion margins were equally delineated by HIS and clinical examination, as confirmed by histopathology. No false negatives were detected when comparing HIS detection with histopathology.

In the false positive case an actinic keratosis and benign lentigo was present histologically on the LM borders which complicated the interpretation of the HIS image.

The lesions were operated in accordance with current standards by removing LMs with 5 mm clinical margins and LMMs with 10 mm margins if anatomically possible (15). As this was a pilot study, the margins given by HIS were not used in the excisions. After receiving the results from the histopathological analyses, 3/14 of the LM lesions and 2/5 LMM lesions needed re-excision because of the subclinical extension of the lesion borders. If the excision borders had been selected on the basis of the HIS analysis, 5 re-excisions could have been avoided (Table I).

Table I. *Lesion characteristics in hyperspectral images (HIS) compared with clinical evaluation*

Patient	Breslow thickness (mm)	HIS useful[a]	HIS provided no additional information[b]	False positive[c]	Re-excision avoidable
1	*In situ*	Wider	–	–	+
2	*In situ*	Wider	–	–	+
7	*In situ*	Wider	–	–	+
16	1.25 mm	Wider	–	–	+
19	0.50 mm	Wider	–	–	+
6	*In situ*	Wider[d]	–	–	–
17	0.75 mm	Wider[d]	–	–	–
4	*In situ*	Smaller	–	–	–
8	*In situ*	Smaller	–	–	–
13	*In situ*	Smaller	–	–	–
3	*In situ*	–	Identical	–	–
5	*In situ*	–	Identical	–	–
9	*In situ*	–	Identical	–	–
11	*In situ*	–	Identical	–	–
14	*In situ*	–	Identical	–	–
15	0.70 mm	–	Identical	–	–
18	0.70 mm	–	Identical	–	–
10	*In situ*	–	Identical	–	–
12	*In situ*	–		+Wider	–

[a]HIS shows lesion margins more accurately compared to clinical evaluation as confirmed histologically. [b]Lesion borders similarly detected clinically, by HIS and histology. [c]HIS shows lesion wider than histologically confirmed. [d]Only minor subclinical extension, no need for re-excision.

DISCUSSION

This study indicates that the HIS is capable of detecting the subclinical borders of LM and LMM. Importantly, in over 50% of the cases, the lesion margins were assessed more accurately by using the HIS than with the clinical methods. The advantages of HIS include a handheld imager with a large field of view (12 cm^2) and a quick imaging process. All studied skin areas including the nose and ears were suitable for imaging with the HIS and fitted the field of view.

The lesions were removed with margins determined after delineating the tumour visually using Wood's light. Three LM patients and 2 LMM patients needed re-excision because of the histologically verified subclinical extension of the lesions. Interestingly, if the patients had initially been operated on using margins given by HIS, the re-excisions could have been avoided. HIS also seems to be inversely useful, since clinical assessments delineated 3 LM lesions incorrectly larger than depicted using HIS and confirmed by histopathology.

Discrimination of LM from sun-damaged skin at the periphery of lesions may also be challenging histologically (3). The cytological atypia in LM may vary and be subtle. The diffuse melanocytic overgrowth of sun-damaged skin and the presence of benign melanocytes along the hair follicles make it challenging to assess the peripheral margins of LM. Immunohistochemistry, for e.g. MART-1, is sometimes used to identify LM. However, also normal, chronically sun-exposed skin has a high number of MART-1 positive melanocytes (16, 17). In one case in our study, benign lentigines and subclinical AK surrounding the LM made it difficult to correctly interpret the HIS image and led to a false positive interpretation. These lesions might have complicated the histopathological analysis as well.

Wood's light turned out to be of only marginal help in assessing the margins of LMs. Especially in cases where also benign lentigines were present, the delineation of LM with Wood's light was complicated. Since both melanin and haemoglobin strongly absorb visible and UV light (4), a future developmental aspect could be to integrate a UV light source to HIS to improve visualisation of the pigmentation.

There are several commercially available devices for skin cancer detection and a magnitude of research in the field (18, 19). As far as we know there are no commercial applications of a HIS. Previously, a few techniques have been used to assess surgical margins includings: dermatoscopy, confocal microscopy and optical coherence tomography.

Dermatoscopy (epiluminescence microscopy) helps in defining the LM borders, but requires an experienced dermatoscopist (20). LM on the face do not show the classical dermoscopic features found on the other parts of the skin, which makes their observation more challenging (21). In this study dermatoscopy was used as a diagnostic aid, but not for the delineation of the lesions.

Confocal microscopy has shown potential in evaluating pigmented skin lesions and their margins (22). The device detects to depths of 300 µm, i.e. to the papillary

dermis. The limitation in confocal microscopy is a small field of view (FOV 8 × 8 mm mosaic composite images) leading to several slow imaging sessions for each lesion. The method lacks any objective analysis and the assessment of one FOV area requires at least 5 min for an expert which makes the method slow compared to HIS (23, 24).

Optical coherence tomography (OCT), has shown potential in delineating the borders of non-melanocytic skin malignancies (25). As far as we know there are no studies of the delineation of pigmented lesions using OCT. The device provides high-resolution cross-sectional images at greater depths (1.5–2 mm) than confocal microscopy. The FOV is small (6 × 6 mm), thus making the imaging process slower than in HIS. The analysis remains subjective.

We have earlier shown that the HIS is useful in the detection of skin field cancerisation (5). In the present study HIS showed its potential in the detection of the subclinical borders of LM and LMM. By detecting accurate margins for the lesions, cumbersome re-excisions could be avoided. In addition, HIS could also be used to spare facial tissue in cases where lesion borders are smaller than shown by clinical assessments. HIS can offer clinicians a practical tool for a non-invasive delineation of tumour borders. As this was a pilot study with limited cases further studies are warranted to validate the results.

ACKNOWLEDGEMENTS

This study was funded by the Novo Nordisk Foundation's Novo PreSeed Grant.

The authors declare no conflicts of interest.

REFERENCES

1. Reed JA, Shea CR. Lentigo maligna melanoma in situ on chronically sun-damaged skin. Arch Pathol Lab Med 2011; 135: 838–841.
2. Swetter SM, Boldrick JC, Jung SY, Egbert BM, Harvell JD. Increasing incidence of lentigo maligna melanoma subtypes: northern California and national trends 1990–2000. J Invest Dermatol 2005; 125: 685–691.
3. Breuninger H, Schlagenhauff B, Stroebel W, Schaumburg-Lever G, Rassner G. Patterns of local horizontal spread of melanomas: consequences for surgery and histopathologic investigation. Am J Surg Pathol 1999; 23: 1493–1498.
4. Parakevas L-R, Halpern AC, Marghoob AA. Utility of Wood´s light: five cases from pigmented lesion clinic. Br J Dermatol 2005; 152: 1039–1044.
5. Neittaanmäki-Perttu N, Grönroos M, Tani T, Pölönen I, Ranki A, Saksela O, et al. Detecting field cancerization using a hyperspectral imaging system. Lasers Surg Med 2013; 45: 410–417.
6. Martin ME, Wabuyele MB, Chen K, Kasili P, Panjehpour M, Phan M, et al. Development of an advanced hyperspectral imaging (HSI) system with applications for cancer detection. Ann Biomed Eng 2006; 34: 1061–1068.
7. Siddiqi AM, Li H, Faruque F, Williams W, Lai K, Hughson M, et al. Use of hyperspectral imaging to distinguish normal, precancerous, and cancerous cells. Cancer 2008; 114: 13–21.
8. Panasyuk SV, Yang S, Faller DV, Ngo D, Lew RA, Freeman J, et al. Medical hyperspectral imaging to facilitate residual tumor identification during surgery. Cancer Biol Ther 2007; 6: 439–446.
9. Fitzpatrick TB. The validity and practicality of sun-reactive skin types I through VI. Arch Dermatol 1988; 124: 869–871.
10. Saari H, Aallos V-V, Holmlund C, Malinen J, Mäkynen J. Handheld hyperspectral imager. Proc SPIE 2010; 7680.
11. Saari H, Pölönen I, Salo H, Honkavaara E, Hakala T, Holmlund C, et al. Miniaturized hyperspectral imager calibration and uav flight campaigns. Proc Spie 2013; 8889: 10–12.
12. Nascimento JMP, Dias JMB. Vertex component analysis: A Fast algorithm to unmix hyperspectral data. IEEE Trans Geosci Remote Sensing 2005; 43: 898–910.
13. Bowles J, Palmadesso P, Antoniades J, BaumbackM, Rickard LJ. Uses of filter vectors in hyperspectral data analysis. Proc SPIE 1995; 2553: 148–157.
14. Bro R, De Jong S. A fast non-negativity-constrained least squares algorithm. J Chemom 1997; 11: 393–401.
15. Bichakjian CK, Halpern AC, Johnson TM, Foote Hood A, Grichnik JM, Swetter SM, et al. American Academy of Dermatology Guidelines of care for the management of primary cutaneous melanoma. J Am Acad Dermatol 2011; 65: 1032–1047.
16. McLeod M, Choudhary S, Giannakakis K, Nouri K. Surgical treatments for lentigo maligna: a review. Dermatol Surg 2011; 37: 1210–1228.
17. Hendi A, Brodland DG, Zitelli JA. Melanocytes in long-standing sun-exposed skin: quantitative analysis using the MART-1 immunostain. Arch Dermatol 2006; 142: 871–876.
18. Calin MA, Parasca SV, Savastru R, Calin MR, Dontu S. Optical techniques for the noninvasive diagnosis of skin cancer. J Cancer Res Clin Oncol 2013; 139: 1083–1104.
19. Ferris LK, Harris RJ. New diagnostic aids for melanoma. Dermatol Clin 2012; 30: 535–545.
20. Robinsson JK. Use of digital epiluminescence microscopy to help define the edge of lentigo maligna. Arch Dermatol 2004; 140: 1095–1100.
21. Pralong P, Bathelier E, Dalle S, Poulalhon N, Debarbieux S, Thomas L. Dermoscopy of lentigo maligna: report of 125 cases. Br J Dermatol 2012; 167: 280–287.
22. Carrera C, Palou J, Malvehy J, Segura S, Aguilera P, Salerni G, et al. Early stages of melanoma on the limbs of high-risk patients: clinical, dermoscopic, reflectance confocal microscopy and histopathological characterization for improved recognition. Acta Derm Venereol 2011; 91: 137–146.
23. Guitera P, Moloney FJ, Menzies SW, Stretch JR, Quinn MJ, Hong A, et al. Improving management and patient care in lentigo maligna by mapping with in vivo confocal microscopy. JAMA Dermatol 2013; 149: 692–698.
24. Carrera C, Puig S, Malhevy J. In vivo confocal reflectance microscopy in melanoma. Dermatol Ther 2012; 25: 410–422.
25. Alawi SA, Kuck M, Warlich C, Batz S, McKenzie G, Fluhr JW, et al. Optical coherence tomography for presurgical margin assessment of non-melanoma skin cancer – a practical approach. Exp Dermatol 2013; 22: 547–551.